

EVALUATION OF MICROSURGERY ON SUPRATENTORIAL
MENINGIOMA UNDER SELECTIVE EMBOLIZATION
PREOPERATION

*Nguyen Xuan Phuong*¹

Summary

Objectives: To evaluate clinical and preclinical characteristics and results of microsurgery of meningioma under preoperative selective embolization. **Subjects and methods:** A descriptive research on 9 patients with meningioma who experienced selective embolization preoperation and microsurgery in Military Hospital 103 from January 2016 to July 2021. Evaluating the tumor extent of resection by Simpson, surgery result by Ojemann. **Results:** Clinical characteristics include consciousness disorder 11.1%, increased intracranial pressure 88.9%, epilepsy 33.3%, movement disorder 33.3% often in the parietal-temporal lobe, psychosis 11.1% often in the frontal lobe. 100% of patients under total resection, medium duration was 155.56 ± 33.58 minutes. Blood transfusion was 0.33 ± 0.5 units. None of the patients had surgery complications postoperation. The good result was 100%. **Conclusion:** Symptomatic meningioma depends on the situation. Preoperative selective embolization enables to decline the surgery duration, blood transfusion, to remove tumor totally, and to have good results post-operation.

* *Keywords: Meningioma; Microsurgery; Endovascular embolization.*

INTRODUCTION

Meningioma is one of the most common tumors of the central nervous system, originating from arachnoid cells of the meninges. Most meningiomas

are benign, whereas malignant tumor is rare. Incidence of meningioma impacts on age, rare in children with a rate under 3% of all intracranial tumors; common in adults and older, making up to 20% of intracranial tumors.

¹Military Hospital 103

Corresponding author: Nguyen Xuan Phuong (xuanphuong.pttk@gmail.com)

Date received: 15/8/2022

Date accepted: 28/9/2022

The primary treatment of meningioma is total resection. For huge tumors with strong angiogenesis, it is difficult to operate, and there is a high risk of bleeding during the operation and post-operation, even mortality.

Hence, preoperative selective embolization in these cases reduced the risk of bleeding, convenient in operating and total removal, leading to good result post-operation. This was confirmed in almost studies in Vietnam and literature worldwide [2, 3].

With these advantages of microsurgery and neuronavigation in operation, we conducted this research: *To describe the clinical and preclinical characteristics of supratentorial meningioma. Evaluate the result of microsurgery in supratentorial meningioma with preoperative selective embolization.*

SUBJECTS AND METHODS

1. Subjects

9 patients with meningioma under selective embolization and microsurgery in Military Hospital 103 from January 2016 to July 2021.

2. Methods

* *Study design:* A retrospective, descriptive study without the control group to point to clinical and preclinical characteristics in diagnosis and treatment.

** Selection criteria:*

Patients were diagnosed with meningioma by clinical characteristics, CT and MRI features.

Patients experienced selective embolization preoperation.

Histological result was meningioma.

** Exclusion criteria:*

Patients were diagnosed with meningioma under no selective embolization preoperation, had combined diseases could not operate, could not perform microsurgery, or histological results were not meningioma.

** Selective embolization preoperation:*

General or local anesthesia. Patients lie supine on the table, placed intravenous line (using Natricloride 0.9%).

** Cerebral angiogram:*

Using the Seldinger technique by entering the femoral artery.

** Technique:*

- Locate the femoral artery puncture above the inguinal ligament at the junction of the anterior superior iliac spine and the femoral artery.

- Incise the skin to insert the catheter into the artery and direct the catheter to the artery that needs imaging and intervention.

- After passing the catheter through the aortic arch, rotate the catheter toward the common carotid artery. From here,

continue directing the catheter into the arteries to be imaged under the guidance of the preceding wire.

- Conduct angiography and evaluate the results after the scan.

** Embolization:*

- After conducting and evaluating the feeding arteries of the tumor, embolization was performed.

- Materials: Relying on characteristics and location for choosing the different materials. Temporary embolic agents (PVA, Spongel, hemostatic cotton), permanent embolic agents (Histoacryl glue, onyx, coil...).

- Evaluation of embolization results: the branches in the tumor and the

feeding pedicles are completely occluded and no longer perfusion. Arterial branches that supply blood to adjacent healthy organs are not blocked.

** Surgery technique:*

Pose:

- Patient pose:

+ General anesthesia.

+ Place the head on Mayfield fixation above the heart.

+ Patients can be placed in a supine, lateral recumbent, or prone position due to tumour location. The operation field is in the highest location and is convenient for surgeons. Avoid stretching and twisting of the veins causing edema during the operation.

Surgical instruments:



Surgical microscope
Pentero P800 - Zeiss.



Remove tumor with an ultrasonic
SOERING knife.

On MRI, most tumors were hypointense on T1 and hyperintense on T2 (77.8%), with vivid contrast enhancement and dural tail signs appearing.

RESULT

Table 1: Extent of tumor resection.

Extent of resection	Number of patients (n)	Rate (%)
Simpson I	7	77.8
Simpson II	2	22.2
Simpson III	0	0.0
Total	9	100.0

Gross total resection (Simpson I and II) was 100%.

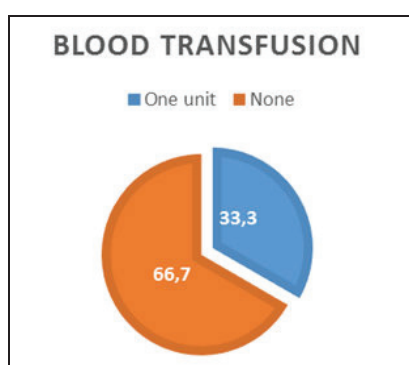


Figure 1: The rate of blood transfusion.

During the operation, there were 3 out of 9 cases under blood transfusion, making up 33.3%. These patients had huge tumors, long duration, a large amount of blood lost, and only needed a unit of blood.

Table 2: Relation between duration and tumor size.

Duration (mins)	Size (cm)			Total
	< 3	3 - 6	> 6	
< 120	0	2 (50)	0 (0)	2 (22.2)
120 - 180	0	2 (50)	3 (60)	2 (55.6)
> 180	0	0 (0)	2 (40)	2 (22.2)
Total	0	4 (100)	5 (100)	9 (100)
p	0.058			

The medium duration was 155.56 minutes.

Table 3: Relation between surgery duration and tumor location.

Duration (min)	Tumor location						Total
	Frontal	Temporal	Parietal	Occipital	Sphenoid wing	Falx cerebri	
< 120	0	0	1 (50)	1 (100)	0	0	2 (2.22)
120 - 180	1 (100)	1 (100)	1 (50)	0	1 (50)	1 (50)	5 (55.6)
> 180	0	0	0	0	1 (50)	1 (50)	2 (22.2)
Total	1 (100)	1 (100)	2 (100)	1 (100)	2 (100)	2 (100)	9 (100)
p	0.575						

Table 4: Outcome when discharged from the hospital.

Surgery result	Number of patients (n)	Rate (%)
Good	9	100.0
Medium	0	0.0
Poor	0	0.0
Total	9	100.0

The good result after surgery was 100%, all patients in our study had no complications postoperation, clinical symptoms were better than preoperation.

DISCUSSION

1. Clinical symptoms

Increased intracranial pressure syndrome (headache, nausea, vomiting) in our study amounted to 88.9%. Our result was similar to Duong Dai Ha (2010), with 91.2% of headaches and 71.6% of vomit. The author believed that headache was the most common symptom but not special for meningioma. Headache is often dull and chronic with vomiting without warning symptoms and often happens in the morning. These symptoms were caused by tumor compressing vessels and were the sign of a huge tumor resulting in increased intracranial pressure syndrome [6].

Consciousness disorder: In our study, only one of the patients had consciousness disorder preoperation. Authors believed that reason for consciousness disorder was a giant tumor or surrounding tumor edema resulting in increased intracranial pressure and brain hernia leading to mortality [6].

With frontal tumors, the common clinical features were mental disorders, thought disorders, movement disorders, and epilepsy were rare. As the mental disorders in old patients were easily

confused with Alzheimer's and corticobasal degeneration, the tumor was easily overlooked, only detected when becoming huge, causing clear increased intracranial pressure. In a temporal-parietal tumor, paralysis and sensation disorders were common. Due to these symptoms, patients presented to the hospital, and the tumor was detected sooner than in the other two locations.

Meningioma, in general, results in epilepsy, especially partial epilepsy. In our study, 33.3% of patients had epilepsy in falx cerebral tumor (two third cases). The mechanism of epilepsy was compressing directly to the meninges stimulating the cerebral cortex or tumor, resulting in increased intracranial pressure leading to epilepsy. Kawaguchi (1996) reported a relationship between surrounding edema and epilepsy [7].

Tumors in the occipital lobe and sphenoid wing often cause vision disorders. These are the symptoms leading to patient's presentation and help detect tumors soon.

In tumor location, there were 44% tumors in a lesser wing of the sphenoid and parasagittal line. According to Shah A, tumors in these locations had feeding vessels from the middle of the

meningeal artery and strong vascular proliferation. These tumors had an indication of preoperative selective embolization for a favorable and safe operation [12].

2. Preclinical features

CT-scan images in our study resembled the authors' about meningioma in general. Many studies have shown that meningioma had a clear boundary, while in our study, the rate was 77.8%. Hyperdense compared with the gray matter was 66.7%, and often there was no or little surrounding edema and vivid enhancement (100%). Our result had 4 out of 9 (44.4%) cases with calcification within the tumor.

Calcification meningioma is one of the factors causing difficulty in total resection. There were 4 in 9 (44.4%) cases having calcification. This was higher than in the research of Hattori K. (2005) (36.3%). This may be reasoned by the number of patients in our study was low [8].

On non-contrast MRI, meningioma images was less specific. On T1W, all tumors were observed to be iso or hypointense. Hyperintense on T2W made up 77.8%. This was the same as other authors: Most meningiomas were hypointense on T1 and hyperintense in T2 when injecting a contrast agent.

The density of meningioma on T1W and T2W has a tendency to resemble adjacent tissue, but the hyper or hypointense of the tumor enables MRI to detect meningioma correctly up to 95%. On MRI, meningioma was often slightly hypointense on T1W and lightly hyperintense on T2W compared with intense gray matter [9, 10].

The dural tail sign was a featured image of meningioma, making up 77.8% of our study. This sign often appeared in convexity and falx cerebri. This result was similar to other authors in that the dural tail was created from the invasion of the tumor and the change in adjacent meninges of the tumor. The authors suggested that invasive meninges should be resected in surgery to avoid recurrence.

3. Results

100% of patients had a good outcome in our study. After embolization, there was no complication such as edema, skin flap necrosis, and infectious incision. These can be explained by the low number of patients in research. According to Raper et al. (2014), there was 0.6% of edema and 0.6% of skin flap necrosis after embolization.

In our study, the medium duration was 155.56 minutes. The average blood transfusion was 0.33 units (≈ 83mL),

lower than in the research by Ishihara (2015), who performed surgery on 56 patients with meningioma under preoperative selective embolization, medium blood transfusion was 407 mL per patient [3]. This can be explained by the average tumor size in our study being smaller than in Ishihara's (62 mm compared with 90 mm), and the number of patients in our study was low.

The extent of total resection (Simpson I and II) in our study was 9 over 0 patients (100%). Authors believed that preoperative selective embolization enables surgeons to control bleeding in operation, lessen the duration, make softer tumor density easier to remove, and reduce blood loss [2, 3].

CONCLUSION

The most common symptoms of meningioma were headache and nausea. Depending on the tumor location, there were different clinical features such as movement disorder, often in the parietal tumor, a mental disorder in the frontal and vision disorder in the occipital or sphenoid wing tumor. Preoperative selective embolization help reduce surgery duration and blood transfusion, remove tumor totally, and gain good result postoperation.

REFERENCES

1. Cushing H. (1938) Meningiomas. Their Classification, Regional Behaviour, Life History, and Surgical End Results. *Bulletin of the Medical Library Association*; 27(2): 185.
2. Raper, D.M., et al. (2014) Preoperative embolization of intracranial meningiomas: Efficacy, technical considerations, and complications. *AJNR Am J Neuroradiol*; 35(9): 1798-1804.
3. Ishihara, H., et al. (2015) The safety and efficacy of preoperative embolization of meningioma with N-butyl cyanoacrylate. *Interv Neuroradiol*; 21(5): 624-630.
4. Simpson D. (1957) The recurrence of intracranial meningiomas after surgical treatment. *Journal of Neurology, Neurosurgery, and Psychiatry*; 20(1): 22-39.
5. Ojemann M.D. (1992) Management of Cranial and Spinal meningiomas: Falx meningioma. *Clinical Neurosurgery*; 40(17): 321-383.
6. Dương Đại Hà. (2010) Nghiên cứu chẩn đoán, kết quả phẫu thuật và yếu tố tiên lượng u màng não tại Bệnh viện Việt Đức. Luận văn Tiến sỹ Y học. Đại học Y Hà Nội.
7. Kawaguchi T., Kameyama S., Tanaka R. (1996) Peritumoral edema

and seizure in patients with cerebral convexity and parasagittal meningiomas. *Neurol Med Chir (Tokyo)*; 36(8): 568-573.

8. Hattori K., Miyachi S., Kobayashi N., et al. (2005) Contralateral meningeal artery supply of paramedian meningiomas. *Surg Neurol*; 64(3): 242-248.

9. Maiuri F., Iaconetta G., Divitiis O., et al. (1999) Intracranial meningiomas: correlations between MR imaging and histology. *Eur J Radiol*; 31(1): 69-75.

10. Watts J., Box G., Galvin A., et al. (2014) Magnetic resonance imaging of meningiomas: a pictorial review. *Insights into Imaging*; 5(1): 113-122.

11. Hurst R W., Rosenwasser R H. (2008) *Interventional Neuroradiology*. Standard Book, Healthcare New York.

12. Shah A., Choudhri O., Jung H., et al. (2015) Preoperative endovascular embolization of meningiomas: Update on therapeutic options. *Neurosurg Focus*; 38(3): E7.