

MINISTRY OF EDUCATION AND TRAINING

MINISTRY OF PUBLIC HEALTH

HANOI MEDICAL UNIVERSITY



NGUYEN THI TO UYEN

**EVALUATION OF RESULTS OF ENDOSCOPIC
TRANSCANAL CANAL WALL DOWN
MASTOIDECTOMY FOR DANGEROUS
CHRONIC OTITIS MEDIA**

Specialization: Ear Nose Throat

Code: 62720155

SUMMARY OF MEDICAL DOCTORAL THESIS

HA NOI - 2018

The work is completed at:
HANOI MEDICAL UNIVERSITY

Instructor: Assoc. Prof. PhD. NGUYEN TAN PHONG

Reviewer 1: Assoc. Prof. PhD. NGHIEM HUU THUAN
Vietnam Military Medical Academy

Reviewer 2: Assoc. Prof. PhD. NGUYEN THI NGOC DUNG
Pham Ngoc Thach University of Medicine

Reviewer 3: Assoc. Prof. PhD. ĐOAN HONG HOA
National Otorhinolaryngology Hospital of Vietnam

The Thesis will be protected at the Thesis-level dissertation board:

Hanoi Medical University

At: h month date year

Can find thesis at:

National Library

Hanoi Medical University Library

Central Medical Information Library

THE PUBLISHED RESEARCH WORKS

RELATED TO THE THESIS TOPIC

1. **Nguyễn Thị Tố Uyên, Nguyễn Tấn Phong** (2012), Kết quả ban đầu của phẫu thuật tiết căn xương chũm tối thiểu đường xuyên ống tai, *Tạp chí Nghiên cứu Y học*, số 78 (1), tr 48-52.
2. **Nguyễn Thị Tố Uyên, Nguyễn Tấn Phong** (2013), Kết quả phẫu thuật tiết căn xương chũm tối thiểu đường xuyên ống tai, *Tạp chí Nghiên cứu Y học*, số 82 (2), tr 64-71.
3. **Nguyễn Thị Tố Uyên, Lương Hồng Châu, Nguyễn Tấn Phong** (2017), Triệu chứng cơ năng của viêm tai giữa mạn tính nguy hiểm được phẫu thuật nội soi tiết căn xương chũm đường xuyên ống tai, *Tạp chí Tai Mũi Họng Việt Nam*, Volume (62-37), N° 3, tr 78-83.
4. **Nguyễn Thị Tố Uyên, Nguyễn Tấn Phong, Đoàn Thị Hồng Hoa, Lê Công Định** (2018), Hình ảnh khám nội soi của viêm tai giữa mạn tính nguy hiểm được phẫu thuật nội soi tiết căn xương chũm đường xuyên ống tai, *Tạp chí Y học Việt Nam*, tập 462, số 1, tr 161-164.
5. **Nguyễn Thị Tố Uyên, Nguyễn Tấn Phong, Cao Minh Thành, Lê Văn Khăng** (2018), Đặc điểm ăn mòn xương trên phim cắt lớp vi tính của viêm tai giữa mạn tính nguy hiểm được phẫu thuật nội soi tiết căn xương chũm đường xuyên ống tai, *Tạp chí Y Dược học Quân sự*, vol 43, số 4, tháng 4, tr 126-131.

QUESTION

Chronic otitis media (COM) is an inflammation that lasts more than 3 months in the middle ear. According to the WHO, COM rate ranges from 1% to 4% depending on the region, Vietnam is 3% to 5%. COM can be dangerous by erosion of the bones which can cause serious complications, surgery indication is absolute, our research refers to 2 diseases: cholesteatoma and grade IV retraction pocket (uncontrolled or precholesteatoma).

In the past, patients often come to treatment when lesion damage and invasive enlargement of the mastoid region even during inflammation stage with serious complications such as meningitis, cerebral abscess ... Today dangerous COM is early diagnosis when the lesions are small and discreet; The CT scan of the temporal bone can determine extent of the lesions (focal or spread), mastoid structure. The change of disease and the development in diagnosis are motivation for improvement in treatment. With severe lesions on the sclerosis mastoid, small antre, post-auricular or antero-auricular mastoidectomy made a big and safe mastoid cavity which is too large for lesions with many disadvantages, on this case, the close technic mastoidectomy is difficult with high risk of complications and will be dangerous if patients do not return periodic examination and take the second look surgery when suspected recurrent cholesteatoma.

Antrotomy transcanal under microscope was reported by Holt J.J in 2008. When compare with post-auricular and antero-auricular, the transcanal is the shortest and direct entrance to antre, and well keeping propre mastoid cortex. Although the endoscopy (1990) was used on ear surgery much later than microscopy (1950), it become the usefull manipulation for endoral and transcanal entrance thanks for small tip and wide field. Nguyen Tan Phong (2009), Tarabachi M. (2010) reported endoscopy transcanal atticotomy, antrotomy. Nguyen Tan Phong (2010), Tarabachi M. (2013) continue to down the posterior canal wall for the endoscopic transcanal canal wall down (ET CWD) mastoidectomy. This operation is addapted with cholesteatoma or grade IV retraction pocket base on schlerose mastoid and small antre which made a small size of

mastoid cavity but ensure control of disease and drainage, rapid recovery time, high aesthetics, can improve hearing. To improve the theoretical, indicative, technical contribution to disseminate surgery in ENT specialist we carry out the topic: **“Evaluation of results of endoscopic transcanal canal wall down mastoidectomy for dangerous chronic otitis media”** with 2 target:

1. Describe the clinical, subclinical characteristics of patients with dangerous chronic otitis media.

2. Evaluation of the results of endoscopic transcanal canal wall down mastoidectomy in patients with chronic otitis media.

THE NEWS CONTRIBUTIONS OF THE THESIS

1. Suggest the indication of ET CWD based on endoscopic exam and temporal bone CT Scan.
2. Contribute to the scientific reasoning, point out the advantages of ET CWD, the difficulties and how to overcome when practice.
3. Confirmed success of improving the hearing by tympanoplasty on the ET CWD at the first surgery.

LAYOUT OF THE THESIS

The thesis includes 132 pages: Question 2 pages; Overview 28 pages; Research subjects and methods 17 pages; Results 37 pages; Discussion 45 pages; Conclusion 2 pages; Recommendations and new contributions of the thesis 1 page. There are 28 pictures, 34 tables, 29 charts. There are 106 references: Vietnamese: 21, English: 72, French: 13.

CHAPTER 1: STUDY OVERVIEW

1.1. Dangerous chronic otitis media:

1.1.1. The concept: *Dangerous chronic otitis media* is a type of COM that is invasive, destroys the surrounding bone and is at risk for complications. Research refers to two prominent diseases are cholesteatoma and grade IV retraction pocket. *Cholesteatoma* is a development of epithelial squamous keratinase (with epidermal origin) in the middle ear. *The retraction pocket*, also known as the local atelectasis,

is divided into four degrees, in which *the fourth degree* is uncontrollable, considered cholesteatoma and the majority of surgeons have a therapeutic view like cholesteatoma. Through research decades, many authors agree with the view that retraction pocket are one of the pathological mechanisms of cholesteatoma. Three characteristics are mobility, self-cleaning, and superinfection that assess the risk of cholesteatoma, with patches of superficial patches and superinfection showing the highest risk.

1.1.3. The formation and progression of cholesteatoma: the squamous cell of the inner layer of cover breaks into the centre, accumulates, grows, and invades the middle ear passively. On the other hand, the outer layer of the shell produces an enzyme that eats away the bone in an active way, cholesteatoma can gradually destroy middle ear structures by passive developing and active destruction of neighboring bone structures.

1.1.5. Clinical characteristics of dangerous chronic otitis media

1.1.5.2. Functional Symptoms: In addition to the classic symptoms can meet dry ear, mild hearing loss or normal hearing in dry cholesteatoma, grade IV retraction pocket.

1.1.5.3. Physical symptoms: Endoscopy can detect dangerous lesions but does not measure the extent of the lesion, but the following images are often present in the localized lesions:

Perforation of eardrum: Pars tensa: postero-supperior, marginal or just below the anterior malleus-atrium ligaments; Pars flaccida: can be erosion the attic wall (solid bone), sometimes scaly (brown, firmly attached).

Perforation of the attic wall: Spongy bone, which may have granule, pus.

Polyp: usually from attic, characteristic, covered with cholesteatoma.

Grade IV retraction pocket: Pars flaccida: “naturally opened attic”, often. Pars tensa: postero-supperior: can invade the pars flaccida; ½ posterior: Easy to skinned the posteior tympanic cavity, type “faux perforation”; postero-inferior, anterio-supperior or total are rare.

1.1.6. The paraclinical characteristics of dangerous COM

1.1.6.1. Tonal audiometry: Frequent transmission or mixt hearing loss, may be normal hearing: ossicular chain is continue or tympan - stape fix.

1.1.6.2. Temporal CT Scanner: cholesteatoma lesions with opaque region in the middle ear or grade IV retraction pocket with hollow (may be partial

opaque) in the attic, the trend is spreading into the aditus, antre; regular erode bones around, rounded bow; erode part or all ossicular.

1.2. Canal wall down mastoidectomy:

1.2.1. History of surgical treatment dangerous COM

CWD mastoidectomy: Zaufal (1890) propose, Bondy (1910) modify, widely used in cholesteatoma safe, less recurrence, however, the posterior access create a wide cavity with many disadvantages. Thanks to the microscope (1950), canal wall up mastoidectomy (CWU) develop with highlights of listening function overwhelmed CWD until 1980, when the defect of recurrence of cholesteatoma and second surgery become clearly, the surgeons comeback CWD with many improvement. Luong Sy Can (1975) discusses overcoming the defect of wide cavity.

CT Scan support the transcanal access under microscope: atticotomy by Tos (1982), Morimitsu (1989); antrotomy by Holt J.J. (2008).

Endoscopy ear surgery: began at 1990 by Takahashi and Thomassin J.M., now it's already popular in the world. Nguyen Tan Phong (2009), Tarabachi M. (2010): transcanal attico-addito-antrotomy. Continue lowering the facial nerve wall, Nguyen Tan Phong (2010), Tarabachi M. (2013) had done ET CWD mastoidectomy. Some Vietnamese surgeons (Cao Minh Thanh, Ho Le Hoai Nhan) also use endoscopy ear surgery for dangerous COM.

1.2.2. Concept of CWD: destroy postero-superior ear canal wall and attic wall, unify mastoid, tympanic cavity and ear canal in unique cavity, lowering the facial nerve wall, meatoplasty; Radical mastoidectomy: remove the eardrum, malleus and enclume, keep the stape, clamped eustachian tube; Modify radical mastoidectomy: keep the eardrum, ossicular chain or tympanoplasty.

1.2.3. The entrance of CWD: 3 types are postaural (drill through mastoid cortex to antre), preaural (drill at the same time the mastoid cortex and postero-anterior ear canal) and transcanal (direct drilling at attic wall and postero-anterior ear canal without removing the mastoid shell).

1.2.4. Endoscopic transcanal canal wall down mastoidectomy

1.2.4.3. Anatomical basis of ET CWD mastoidectomy

According to Legent, Ngo Manh Son, Tran To Dung average mastoid cortex thickness is 12.41 ± 1.6 mm and split wall between antre and ear canal thickness is just about 2 – 4 mm. Compared to the classic postaural entrance, *transcanal is the shortest access to antre.*

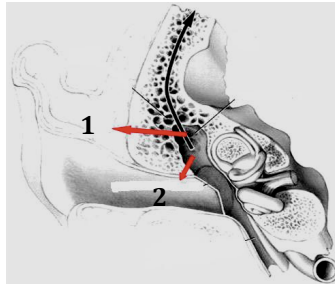


Figure 1.6. Vertical horizontal slice temporal bone and middle ear: 1. Access to antre from outside of the mastoid; 2. Access to antre transcanal.
 Source: Nguyen Tan Phong (2010) *miniradical mastoidectomy with tympanoplasty*, YHTH magazine 730(8).

Prolonged inflammation restricts the development of cells, osteitis lead to bone formation reaction, calcium deposition make higher bone density. Tran To Dung: more than 80% solid mastoid have antral bottom higher than canal floor (62,5% in the middle 1/3 canal wall). ***Solid mastoid often included small antre with bottom higher than canal floor so the CWD cavity will be small, easily ensure drainage.***

1.2.4.5. Application endoscope in CWD mastoidectomy: With wide viewing angles and flexible viewing position, endoscopy has made the transcanal more effective. When applied in CWD, instead of destroy normal bone of mastoid cortex, just direct drilling at attic wall and postero-anterior canal wall, it was revealed all the attique, aditus, antre. Down the facial nerve wall and do tympanoplasty are easy with endoscopy surgery. However, ET CWD only for the solid mastoid with small antre. Difference point with microscopy surgery also the difficulty of endoscopy is having only one hand for used micro instrument but it were overcome by own technique. For successful application, the surgeons should be updated need to improve the anatomical knowledge.

CHAPTER 2: OBJECTIVES AND RESEARCH METHODS

2.1. Research subjects: 54 patients with 57 ears are diagnosed COM with cholesteatoma or grade IV retraction pocket which are performed endoscopy transcanal canal wall down mastoidectomy at the ENT National Hospital from September 2010 to September 2013.

2.1.1. Selection criteria

- Patients are diagnosed COM with cholesteatoma or grade IV retraction pocket:

+ Clinical: at least 1 of endoscopic lesions: *Pars tensa*: marginal perforation, nacre pus or uncontrolled retraction pocket; *Pars flaccida*: perforation or uncontrolled retraction pocket; *Erosion of attical wall*.

+ Tonal audiograms: no limit of type and level of hearing loss but does not include progressive lesions of cochlear or auditory nerve or intracranial.

+ CT Scan: Translucent blocks or hollow cavity in the middle ear which *erosion bone*: ossicular chain, attical wall, middle ear, external semi-circular canal, fallop; *mastoid structure*: compact or poor cell (but compact in facial wall for transcanal entrance, small antre.

+ Evaluation in operation: local lesion, solid mastoid, small antre.

- Be done ET CWD mastoidectomy, followed and evaluated post-op.

- Patients and caregivers (if ≤ 18 years) agree to participate in the study.

2.1.2. Exclusion criteria: are in inflammatory or dangerous complication such as meningitis, brain abscess, atrial fibrillation... ; have deformed outer ear, middle ear; don't follow up until the operation stable, not evaluated at 3 months post operation.

2.2. Research methods

2.2.1. Research design: prospective, intervention.

2.2.2. Choose a convenient template: There were 54 patients with 57 diseases ears, 3 patients were bilateral operated. All 57 ears were evaluated at 3 months; 50/57 at least 1 year of follow up.

2.2.4. Research steps

2.2.4.1. Data collection before surgery: Functional symptoms; Endoscopy for ear surgery and ear opposite; Tonal audiometry; Temporal bone CT.

2.2.4.2. Steps of endoscopy transcanal CWD mastoidectomy

Incision: *Endaural access:* creating a V flap at postero-superior of external auditory canal (EAC) which is closed tympanal frame (from 6h to 13h at right ear or 11h at left ear), reveal the attic wall, postero-superior EAC and tympanic cavity; ***Endo-anterior access:*** Make a cut from the top of the V flap to the anterior groove of the ear.

Disclosure and remove lesions mastoiditis: Drilling from front to back, starting at the attical wall, disclosure and tracing from attic to additus and antre; Remove the lesions from the back to the front, trying to peel the whole all cholesteatoma wrap or retraction pocket; Remove the injured ossicle, absolutely do not remove the pedal out of the oval window.

Complete the CWD cavity: Drill down the nerve facial wall (with antral bottom is higher than or equal ear canal floor) to create the drainage. The 2nd and 3rd sections of facial nerve divide the bottom of cavity into two parts: the antero-inferior (meso-hypotympany – where reconstruct the small atrium); postero-supperior (attico-addito-antral mix into the canal).

Tympanoplasty: when there aren't cholesteatoma in the middle and hypotympany, applied 4 types tympanoplasty but instead of the eardrum covering the entire tympanic cavity, on the CWD mastoidectomy the tympanic membrane cover only the middle and hypotympany (small tympanic cavity) because the attic be opened into the ear canal with additus and antre. Type I: miryngoplasty; type II, III: + reconstruction ossicular colume; type IV: form the mini tympan for hypotympany (including round windows and Estachian hole)..

Materials for eardrum reconstruction: reusing the eardrum – canal flap or shaping the eardrum at cartilage, pericartilage, temporal fascia.

Material for ossiculair reconstruction: the ceramic biological or mastoid bone or cartilage fragments (don't reuse incus or malleus because of remnent cholesteatoma or retraction pocket). The chain will remain if it's continuous, good mobility and ensure complete removal of the pocket.

Place ventilation tube: tympanoplasty but suspected function of Eustachian tube.

Clog up Eustachian hole: when dermatitis all the hypotympany.

Meatoplasty: drilling process in CWD mastoidectomy was enlarged the ear canal bone. When soft ear canal is narrow, the incision in the roof makes it wider, that is “outer cartilage meatoplasty”.

2.2.4.3. Evaluation of surgical results

* **During surgery:** Detailed records of lesions, injury of bone chain, attic wall, middle ear roof, canal semicircular and the VII; mastoid structure, antre size, antre bottom position. Difficulties and advantages.

* **Postoperative period:** Monitoring complications: wound infection, vestibular disorders, facial nerve peripheral paralysis... Monitor the recovery of operation cavity.

* **After surgery for 3 months:** functional symptoms; endoscopy: moist or dry cavity, full or partial skin recover, eardrum status (tympanoplasty).

* **After surgery for over a year:** ask for functional symptoms, ear endoscopy, tonal audiometry, cranial MRI with diffusion.

*** Criteria for evaluation:**

Eardrum: Good: transparent or thick, with calcified but not collapse, not punctured, do not recur cholesteatoma; Fair: atelectasis degree I, II; Average: non marginal perforation, atelectasis degree III, IV; Failure: atelectasis degree IV or recurrent cholesteatoma.

Radical cavity: Good: dry, clean; Fair: Earwax; Medium: fungal infection or bacterial infection; Failure: recurrent cholesteatoma.

Tonal audiometry: Audiology evaluation post operation according to Committee on Hearing and Equilibrium of American with PTA was the mean of air conductive threshold and ABG was the mean distance between air and bones conductive threshold at 500, 1000, 2000, 4000 Hz. PTA and ABG: Very good: ≤ 10 dB; Good: 11 - 20 dB; Medium: 21 - 30 dB; Poor: 31 - 40 dB; Very poor: $ABG \geq 41$ dB. When $PTA \leq 30$ dB, $ABG \leq 20$ dB: successful surgery.

Bone conductive reserve (median baseline hearing at 500, 1000, 2000 and 4000 Hz) assessed the effects of surgery on the inner ear.

Cranial MRI diffusion: Good: no cholesteatoma recurrence; Poor: cholesteatoma recurrence.

2.2.5. Data analysis: using SPSS 20.0.0 software.

2.2.8. Study diagrams:

Endoscopic examination ears: there is at least one lesion below:

Pars flacida: perforation/ flakes difficult to obtain/ polyps/ retraction pocket uncontrollably.

Pars tensa: perforation marginal, late white pus/ uncontrolled retraction pocket.

Attical walls: erode or perforation.

Tonal audiometry:

3 type of hearing loss

Temporal bone CT Scan:

- Blurred or hollow cavities erode ossicular and the middle ear bone.

- Local lesions in tympany, attic, additus, antre

- Mastoide ivory or poor cellular, small antre.

ENDOSCOPIC TRANSCANAL CANAL WALL DOWN MASTOICDECTOMY

Accessement cavity middle and lower atrium in PT: longer cholesteatoma or not

No longer

Cholesteatoma at oval window

Cholesteatoma at Eustachian tube

Tympanoplasty type I, II, III

Tympanoplasty type IV

Close Eustachian tube

Assessment postoperative stage: fonction symptoms, complications

Postoperative evaluation 3 months: functional symptoms, endoscopy

Postoperative evaluation 1 year: functional symptoms, endoscopy, audiometry

CHAPTER 3: RESEARCH RESULTS

3.1. The clinical, subclinical characteristics of dangerous COM

3.1.1. General characteristics: 54 patients, 57 ears (3 patients were operated bilateral ears).

Age: The smallest is 16, the oldest is 71, the average is 39.8 ± 14.7 years.

Duration of illness: from 1 year to 40 years, average 11.7 ± 9.9 years.

3.1.2. Functional Symptoms

3.1.2.2. Frequency of functional symptoms

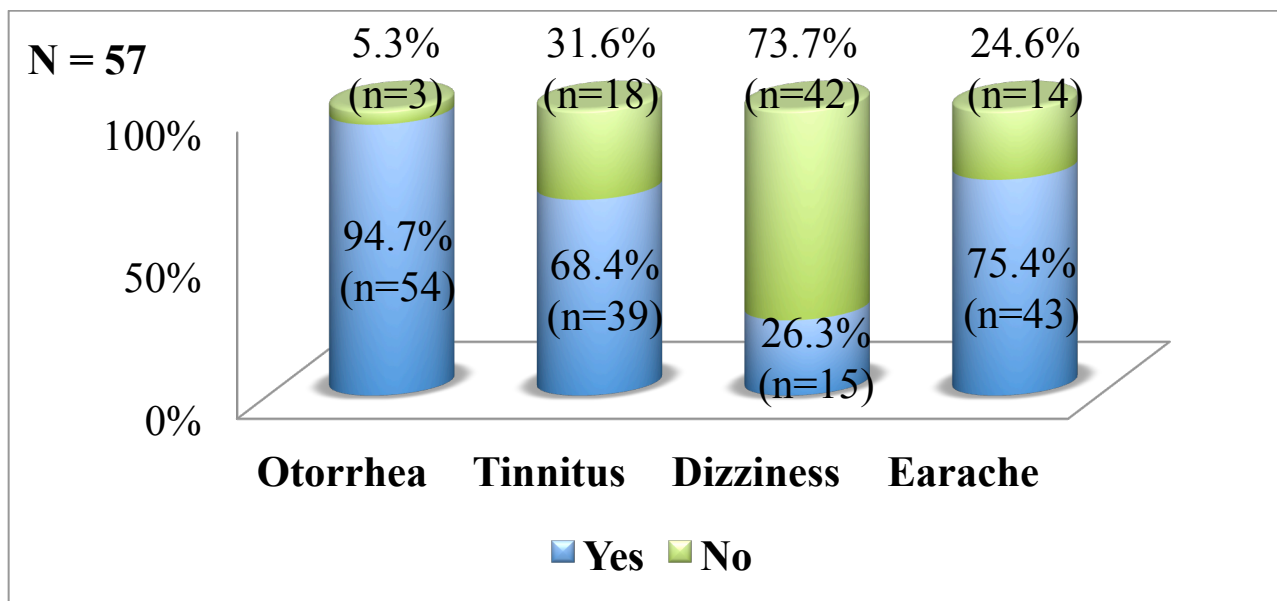


Figure 3.6. Prevalence of pre-op functional symptoms

3.1.3. Pre-op ear endoscopy: All 57 ears are dangerous lesions at least 1 in 3 position in pars tensa, pars flaccida and attical wall.

Table 3.4. Prevalence of pars tensa's lesions at endoscopy

<i>Pars tensa</i>	Polyp	Perforation	Adhesive	Cholesteatoma	Normal	N
n	1	5	41	6	4	57
%	1.8	8.8	71.9	10.5	7.0	100

Table 3.5. Prevalence of pars flaccida's lesions at endoscopy

<i>Pars flaccida</i>	Cholesteatoma	Retracted pocket	Scales	Polyp	Normal	N
n	29	13	5	7	3	57
%	50.9	22.8	8.8	12.3	5.3	100

Table 3.6. Rate of attical and postero-superior canal wall damage

Ear canal	Corroded attical wall	Corroded postero-superior wall	Hard to judge	Normal	N
n	44	1	8	4	57
%	77.2	1.8	14.0	7.0	100

3.1.4. Pre-op hearing

3.1.4.1. Types of hearing loss: conductive 42.1%; mixture of 54.4%; deep reception 3.5%.

Pre-op PTA: conductive groups is 40.6 ± 13.7 dB, mixed groups is 59.6 ± 12.4 dB.

Pre-op ABG: conductive group is 31.5 ± 13.1 dB and mixture group is 33.3 ± 10.6 dB.

Mean ABG of conductive and mixed hearing loss: 32.5 ± 11.6 dB.

3.1.5. Computed tomography of the temporal bone:

3.1.5.1. CT Scan and dangerous COM diagnose: Damage to the middle ear wall: film accurately measured the corrosion of attical wall (94.7%) and middle ear roof (opened meninges) 17.6%; 7 out of 57 cases (12.3%) had corrosion of semi-circular canal, only 5 cases were found at op. Only 15.8% opened 2nd segment, but 35.1% of the film accurately measured (55.6% sensitivity and 68.8% specificity). **Image of bones chain injury:** The film was 61.4% discontinuous, 15.8% suspected and 22.8% continuous, compared with observation at op which the film had a sensitivity of 90.2%, specificity of 56 % with $p < 0.01$.

3.1.5.2. CT Scan and indication of ET CWD mastoidectomy

* **Bone density of mastoid:** high density 79.0%; low density 21.0%.

* **Antre characteristics:** No antre 8.8%, with antre 91.2% (52/57 ears).

Antre size: With N = 52, versus external ear canal: 51.9% smaller; 40.4% equal; 7.7% slightly larger. On operation: 65.4% small, 34.6% medium, no case large or very large. $\frac{1}{2}$ cases which have antre equal and all cases which are slightly larger than ear canal on films are medium size at operation, $p < 0.01$.

Antral bottom position: on CT Scan: 76.9% higher or par 1/3 superior, 17.3% at the level of 1/3 middle and 5.8% at 1/3 inferior of the ear canal. On operation, antral bottom were compared to floor of ear canal:

92.3% higher, 7.7% at the level of floor and no case is lower. Some antral bottom at the level of 1/3 middle and most at the level of 1/3 inferior of the canal on CT scan were equal canal floor on operation, $p < 0.01$.

*** Narrow mastoid entries:**

Meninge down low: 29.8% higher or at the level of the roof of middle ear (Figure 3.1); 56.2% lower than the roof of middle ear (Figure 3.2); 14% close to the top edge of ear canal (Figure 3.3).

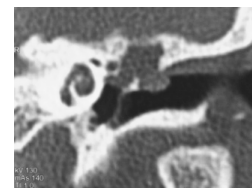
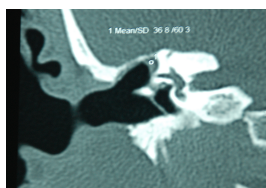
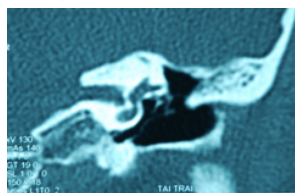


Figure 3.1.(Pt No.16) Figure 3.2.(Pt No. 3) Figure 3.3.(Pt No. 41)

Sigma sinus encroachment forward: on axial slices: 68.4% vein located behind the antrum (Figure 3.4); 17.6% at the level of antral posterior edge (Figure 3.5); 14% front of antral posterior edge (Figure 3.6).

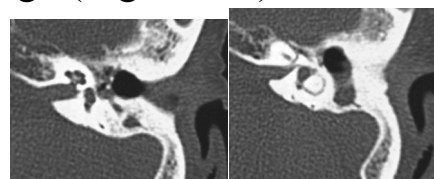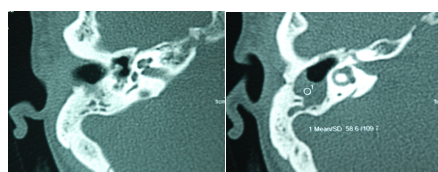
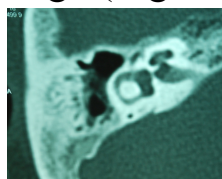


Figure 3.4.(Pt No. 13) Figure 3.5.(Pt No. 3) Figure 3.6.(Pt No. 28)

3.2. Results of endoscopic transcanal canal wall down mastoidectomy

3.2.1. Surgical procedure:

3.2.1.3. Bone damage on operation: all the ear suffered from with varying degrees: 96.5% of bone chain were worn, of which 68.4% were discontinuous, 28.1% were continuous; 3.5% chain integrity but rigid joints. The most abrasion was incus 94.7%; followed by malleus 68.4%; At least 31.6% of stapes (except the food).

3.2.1.4. Middle ear reconstruction

Table 3.21. Rate of middle ear reconstruction

	Tympanoplasty				Clog up Eustachian tube	Total
	Type I	Type II	Type III	Type IV		
n	5	6	29	13	4	57
%	8.8	10.5	50.9	22.8	7.0	100

Ossiculoplasty: 35/57 ears (61.4%), with 12 ears which chain were continuous but cholesteatoma cling to, 21 ears were discontinuous chain

and 2 ears were stiff articulation (type II, III). 20/57 ears (35.1%) chain were discontinued but not reconstruction (type I, IV). Maintain 2/57 ears (3.5%) of continuous and normal vibration chain (type I).

3.2.2. Follow up the results of surgery

3.2.2.1. Catastrophe and complication: 2/57 ears (3.5%): 1 facial paralysie grade IV, complete recovery after a month and 1 cartilagenous inflammation.

3.2.2.2. Evaluation in the postoperative period

Inflammatory exudate flow time:




Figure 3.23. Time distribution of inflammatory exudate post-op

Covered cavity time: Average: 5.44 ± 0.14 weeks. The earliest is 4 weeks (12/57 ears $\approx 21.1\%$) and the latest is 8 weeks (1/57 ears $\approx 1.8\%$).

3.2.2.3. Evaluation post-op over a year: All 54 patients with 57 ears examination regularly in 2 - 3 months until the operative cavity is stable, then 47 Bn with 50 ears involved full schedule of at least 1 year, N = 50. Telephone conversations with 7 patients were not re-examined: any case have otorrhea or discomfort, 4/7 ears improved hearing.

Long terme follow-up: 35.1 ± 9.3 months ≈ 3 years, (12 - 50 months).

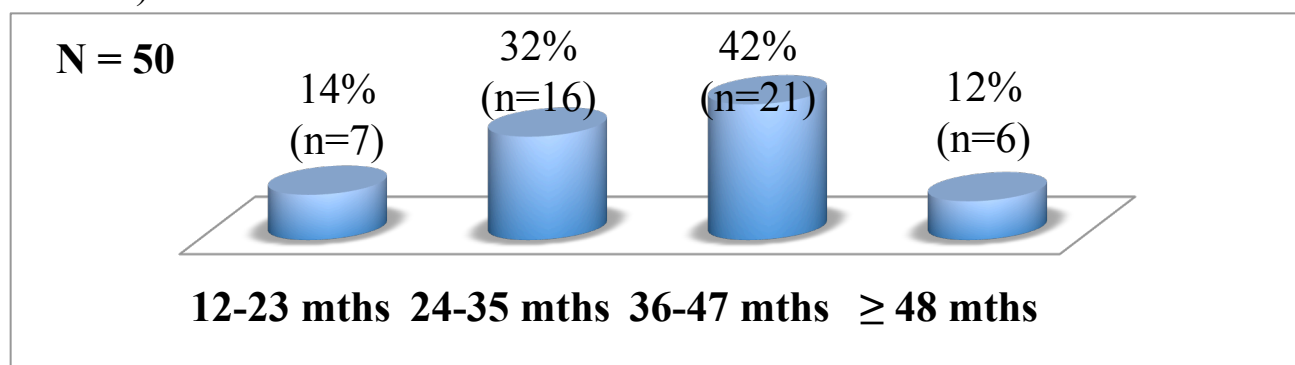


Figure 3.25. The long-term follow-up rate distribute over time

- Functional symptoms:

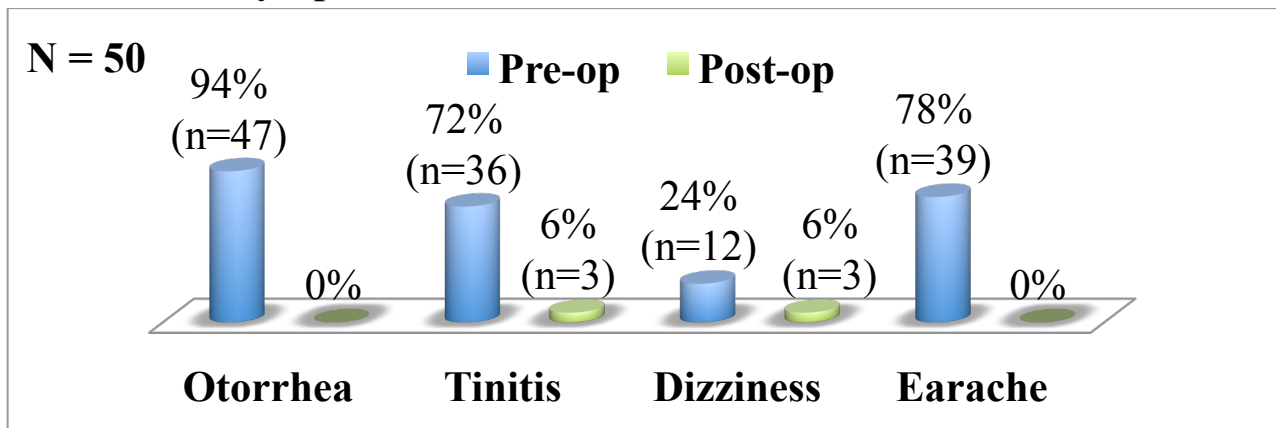


Figure 3.26. Prevalence of pre-op and post-op functional symptom

- Endoscopic examination:

+ Status of radical mastoidectomies cavity:

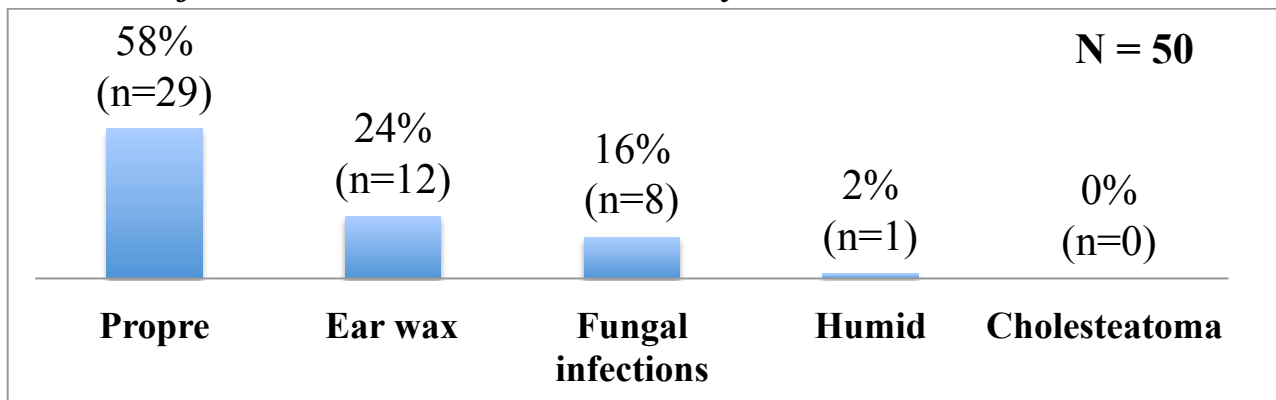


Figure 3.27. Evaluate the status cavity post-op a year

Eardrum status in type I, II, III: 35/40 ear is fully followed up, N = 35. Good results: 57.2% normal; Fair: 34.2% retracted degrees I and II; Average: 8.6% perforation antero-inferior; No case of failure due to recurrent cholesteatoma.

Eardrum status in type IV: 11/13 re-examined at the end of the research: 4/11 ears (36.4%) eardrum retracted and cover the eustachian tube, 7/11 ears (63.6%) eardrum stable, middle-lower cavity clean, non-recurrent cholesteatoma.

+ Tympanal status in closed eustachian tube: 4/4 of the epidermis, clean.

- Cranial MRI diffusion: 46/50 ears (92%) most of the eardrum reconstruct by cartilage. No recurrence of cholesteatoma.

3.2.2.4. Comparing of hearing before and after surgery

N = 50, different between pre and post-op = 0.05 ± 8.2 dB.

Transformation of audiograms in type I, II, III: N = 34.

+ Improvement of PTA:

Pre-op: 46.6 ± 16.3 dB, post-op: 41.3 ± 17.9 dB, effective: 5.3 ± 13.5 dB.

PTA post-op: good results (11 - 20 dB) 8.8%; pretty (21 - 30 dB): 26.5%; Poor (31 - 40 dB): 17.6% and very poor (PTA > 41 dB): 47%.

Table 3.31. Evaluation of PTA by pre- and post-op value range in types I, II, III

PTA	Pre-operation				Post-operation			
	n	%	Accumulative		n	%	Accumulative	
			N	%			N	%
11 – 20 dB					3	8.8	3	8.8
21 – 30 dB	9	26.5	9	26.5	9	26.5	12	35.3
31 – 40 dB	5	14.7	14	41.2	6	17.6	18	52.9
41 – 50 dB	1	2.9	15	44.1	6	17.6	24	70.6
51 – 60 dB	13	38.2	28	82.4	4	11.8	28	82.4
> 60 dB	6	17.6	34	100	6	17.6	34	100
Sum	34	100			34	100		

+ Improvement of ABG:

Pre-op: 30.6 ± 11.1 dB; post-op: 24.0 ± 9.8 dB; Improved: 6.5 ± 13.5 dB.

ABG post-op: good results (11 - 20 dB): 50%, quite (21-30 dB): 20.6%, poor (31 - 40 dB): 17.6%, very poor (≥ 41 dB): 11.8%.

Table 3.32. Assessment of ABG by value range pre and post-op in types I, II, III

ABG	Pre-operation				Post-operation			
	n	%	Accumulative		n	%	Accumulative	
			n	%			n	%
11 – 20 dB	7	20.6	7	20.6	17	50.0	17	50.0
21 – 30 dB	12	35.3	19	55.9	7	20.6	24	70.6
31 – 40 dB	9	26.5	28	82.4	6	17.6	30	88.2
41 – 50 dB	4	11.8	32	94.1	4	11.8	34	100
51 – 60 dB	2	5.9	34	100	0	0.0		
Sum	34	100			34	100		

Hearing change pre and post-op in type IV and close eustachian tube:

- Type IV: bone conduction threshold good up to 2.7 ± 10.7 dB PTA good up to 3.0 ± 10.8 dB, ABG good up to 0.2 ± 9.6 dB.
- Closed eustachian tube: bone conduction threshold good up to 2.5 ± 6.9 dB, PTA reduced to 5.9 ± 24.3 dB, and ABG decreased by 8.4 ± 22.3 dB.
- The difference between type IV and closed eustachian tube group is not statistically significant, $p > 0.05$.

CHAPTER 4: DISCUSSION

4.1. Clinical and paraclinical characteristics of COM patients are applied endoscopic transcanal CWD mastoidectomy

4.1.1. General characteristics: There were 54 patients in which 51 with one ear and 3 with 2 ears, so we have 57 selected ears, $N = 57$.

Age: The mean was 39.8 ± 14.7 years ($N = 54$), equivalent to Ho Le Hoai Nhan 40.5 ± 15 years and Holt J.J. 38.7 ± 19.7 years. The majority (70.5%) at the age of working 20-49 years, the group 30- 39 years of age accounted for 37%. This is a initial research, so it is not recommended for children, at least 16 years of age. The oldest is 71 years old (second ear surgery at 73 years old). ET CWD is applicable in elderly patients.

Opposite ear: 50% were or are at risk of dangerous COM, reflecting status of eustachian tube and nasopharynx, affects to surgery indication.

4.1.2. Functional symptoms: Even if symptoms are not adequate, atypical cholesteatoma need to examine and find dangerous COM. No otorrhea 5.3%, translucent fluid 20.4%, ear flow not rotten 42.6%; not dizzy 73.6%; no pain 24.6%

4.1.3. Pre-op endoscopy: at least one dangerous lesion of the three sites: the most common were pars flaccida with 93% (50.9% cholesteatoma, 21.1% grade IV, 12.3% polyps, 8.8% dark brown scales and tend to erode attical wall (77.2% sure, 14% suspected), only a few have dangerous lesion in pars tensa (10.5% cholesteatoma, 1.8% polyp cover, 17.5% reduction in IV). It can be said that most ear infections cholesteatoma or grade IV were selected to apply ET CWD with lesion in attic.

4.1.4. Preoperative Hearing

4.1.4.3. Pre-op PTA: conductive hearing loss group: 40.6 ± 13.7 (slight), mixte hearing loss group: 59.6 ± 12.4 dB (moderate).

4.1.4.4. Pre-op ABG: conductive and mixte hearing loss group: 32.5 ± 11.6 dB (discotinuos COM of Cao Minh Thanh is 42.19 ± 7.69). Cholesteatoma and grade IV retraction pocket often go together with slack pars tensa, when the ossicular chain is interrupted the membranes will touch on the rest of chain and leading to the transmission of sound. As such, dangerous COM with ABG < 35 dB still has discontinuous chain.

4.1.5. Temporal bone CT Scan

4.1.5.1. The role of CT Scan in the diagnosis of dangerous COM: a translucent block or empty cavity in the middle ear with features:

* **Wall bone erosion of the middle ear:** deliberately chosen the negligible and localized lesion in accordance with the entrance of surgery, so the film only see the erosion of attical wall, semi-circular canal, Fallop tube of 2nd segment of VII, middle ear ceiling; No case worn the antral posterior wall which cause opened the sigma sinus or leaked out the mastoid surface.

* **Ossicular chain erosion:** visible on film with high ratio.

4.1.5.2. CT Scan and ET CWD mastoidectomy

* **Feature of mastoid structure:** Based on CT Scan, besides compact mastoid, we selected some cases of poor cell bone but compact in the region of attical wall and postero-superior wall of ear canal (21%) so on the operation, all the 57 ears have compact bone. Thus, it is possible to designate the ET CWD mastoidectomy in the compact mastoid or some poor cell mastoid which cell groups are not on the surgery entrance.

* **Feature of antre:**

- **Antral size compared to external ear canal:** Since no document has been found on how to measure antral size on CT Scan and to select small antre cases responding to surgery's indication, we used the ear canal size for comparison. If the antre is equivalent to the ear canal, when the skin complete covering, the cavity is only twice as wide of the ear canal.

- **Location of the antral bottom against the posterior wall of the ear canal:** We used the continuous slices of Coronal and Axial position. If the antral bottom on level of one-third inferior of ear canal on film it will

often equal ear canal floor on operation. We didn't choose the ear with antral bottom lower than ear canal floor.

In summary, based on Coronal and Axial position on CT Scan, only designate the ET CWD mastoidectomy for the cases which antre is smaller, equal or slightly larger than the ear canal and the antral bottom is as high as possible or equal to the ear canal floor level.

* **Narrow mastoidectomy entrance:** When the mastoid is compact, the small antre may experience lowering meninge, encroached sigma sinus... making it difficult for the posterior mastoidectomy entrance.

- **Meninge down low:** On the Coronal plane, use the middle ear ceiling and the superior wall of ear canal to compare the position of the meninges. There are 70% meninges which outside the antre lower than the middle ear ceiling, and even 14% of them close to the ear canal.

- **Sigma sinus encroachment forward:** on the Axial plane, an imaginary line passing through the posterior wall of the antre parallel to the posterior wall of the ear canal, the sigma sinus as far away from this line means that more behind the posterior wall of antre, drilling the mastoid as easy. There are no difficult to apply transcanal entrance for 31.6% of sigma sinus encroachment forward with 17.6% same lever and 14% crossing this line.

In summary, in the CT Scan that the meninge close to ear canal and the sigmoid sinus encroache on the front of posterior wall of the antre, the transcanal radical mastoidectomy with endoscopy is the optimal choice because of avoiding meninges, sigmoid sinus and still control of lesions.

4.2. Treatment results of ET CWD mastoidectomy

4.2.1. Surgical process

4.2.1.1. Skin incision and meatotomy: 100% of the incision are in the ear canal make a V skin flap, 33.3% of the incision are pulled to anterior ear groove for a wider operative view and and also “meatotomy outside the cartilage”, do not deform the ear, ensure aesthetics, suitable for small radical mastoid cavity (Va/S rational).

4.2.1.2. Drill technic of transcanal entrance

Advantages of transcanal entrance: expressed in the safety. The posterior entrance should be noted within the surgical triangle to avoid expose the temporal lobe (superior), sigmoid sinus (posterior), the elbow and the 3rd

segment of facial nerve (anterior) while the transcanal entrance starts from the attical wall (usually at the corroded bones) to aditus – ante, plus a wide angle viewer of endoscope should avoid the PT incident on.

Difficulties and how to fix: the anatomical points is different with microscopic surgery, should be update the anatomical knowledge of endoscopic surgery. In the endoscopy, there is only one hand to use microsurgical instruments but it will be easier when apply the endoscopic ear surgery technique. The drilling speed should be slow to control and avoid collision with the optic. (We didn't meet this problem and the surgical time is short because the bone have to removed less than the postauricular entrance). There is a risk of skin erosion due to drilling, for the apprentice should be longer the incision to the ear anterior groove.

4.2.1.6. Middle ear reconstruction: recovery partial anatomy, physiology.

* **Tympanic membrane:** most used under-lay techniques (except the external ear canal - eardrum flap) which are not only suitable for unique hand using microsurgical instruments but also avoids epidermal ectopic.

* **Ossicular reconstruction:** There are 35 ears in which 21 interrupted, 12 continuous and vibrant but can't clean the cholesteatoma or retraction pocket, and 2 intact bone but immovable except the stape. In addition, 2 cases which ossicular chains were partial worn but continuous and vibrant are retained after total remove of cholesteatoma. Obholzer R.: 32 cholesteatoma with continuous and vibrant chains: 53.2% displacement (for radical removal of cholesteatoma), 46.8% remain the ossicular.

Ossicular reconstructive materials: 9 ears using bio-ceramic pillar (successfully applied by Nguyen Tan Phong, Cao Minh Thanh and Le Cong Dinh). In order to limit grafted rejection due to inflammatory in the middle ear, we use cartilage to lay-over the crest of staped and in contact with the eardrum, it help to supporting and strengthening the eardrum. Obholzer R. and Becvarovski also reconstruct the acoustic system with cartilage or eardrums placing directly on the stape.

4.2.2. Follow up the results of surgery

4.2.2.1. Catastrophe and complication: There is 1 case (1.8%) of paralysis peripheral facial nerve grade 4 which completely recovered after 1 month. Kos M.I.: 0.3% but failed to recover, Mukherjee P.: 3% with recovered

after 2 months. Transcanal entrance is outside of the facial nerve so it relatively safe. However when lowering the wall should be drill carefully and pump enough water to avoid heating the nerve.

4.2.2.2. Evaluation in the postoperative period

- **Inflammatory exudate flow:** 77.2% does not flow. The incidence and timing of flow was much less than that of the posterior or anterior CWD technic (thanks to using a small cavity (\approx twice of the ear canal volume)).

- **Time for skin covering the cavity:** over half of cases in 5 weeks and 82.4% in 6 weeks, significantly shorter than other CWD technic. Beside the small cavity advantage, we use temporal fascia or pericartilage or cartilage to lining and maximum reuse the ear canal skin flap to cover.

4.2.2.3. Stability of CWD cavity: assessed at 50 ears which follow at least 1 year with functional symptoms, endoscopy, audiometry.

- **Postoperative follow-up time:** mean 35.1 ± 9.3 months (\approx 3 years, 12 to 50 months), of which 86% followed at least 2 years, more than half (54%) followed at least 3 years (including 6 ears (12%) over 4 years (Figure 3)).

- **Improvement of functional symptoms:** relatively clear, pre-op are 94% otorrhea and 78% earache, but post-op there are any symptom. Tinnitus was reduced from 72% to 6% and dizziness decreased from 24% to 6%.

- **Endoscopic evaluation of CWD cavity:** 82% stable (clean or little ear wax), Maniu A.: 87.5% stable. Medial results: 2% (1 ear) moist, 16% fungal infection (local treatment only). No case of failure due to recurrent cholesteatoma. Stability cavity demonstrated that ET CWD mastoidectomy has ensured the technical standards such as lowering the facial nerve wall so that the antre drain into the ear canal, opening all narrow corners and making sure ear orifice width (Va/S reasonable).

4.2.2.4. Status of tympanic membrane in the tympanoplasty group:

Tympanoplasty type I, II, III: N = 35. 57.2% good results with normal eardrums that indicate steady state of the tympanic mucosa and Eustachian function. 34.2% quite good with grade I, II atelectasis (without grade III, IV), recurrent atelectasis is difficult problems, Holt J.J.: 12.7% of atelectasis and 12.7% of effusion otitis. Medial results: 3 ears (8.6%) had small perforations that equivalent to 7.3% of Kos M.I.

Type IV: Tympanic cavity is very small so easily affected by Eustachian tube function: tympanic membrane tends to pull on, 4/11 ears the tympanic membrane cover the Eustachian hole.

4.2.2.5. Cholesteatoma recurrence: assessed by endoscopy, MRI diffusion and 2nd surgery. With an average follow-up of 3 years, we have not detected any case of cholesteatoma recurrence, while Kos M.I.: 6.1% (follow-up from 1 to 24 years, average 7 years), Chang CC. & Chen MK.: 3.8% (follow-up over 1 year), Young M.: 3.7% (follow-up for 5 years).

4.2.2.6. Change in audiometry post-op: 50 ears follow-up at least a year.

- **Bone conduction reserve (threshold):** with N = 50, almost unchanged between before and after surgery (deviation of 0.05 ± 8.2 dB with $p > 0.05$) so there aren't inner ear's complications no damage to the hearing cells. This result partly confirms the safety of ET CWD mastoidectomy.

- **Hearing changes in tympanoplasty type I, II, and III:** N = 34, eardrum reconstruction with ossicular preservation or reconstruction are initially successful.

Improvement of PTA: The average PTA pre-op is 46.6 ± 16.3 dB and post-op is 41.3 ± 17.9 dB so PTA improved 5.3 ± 13.5 dB.

PTA evaluation pre-op and post-op according to value range: Table 5, no case less than 10 dB. With the PTA in the range of 11 - 20 dB (normal hearing): pre-op any case but post-op has 3 ears (8.8%). With $PTA \leq 30$ dB (slight hearing loss, according to Committee on Hearing and Equilibrium guidelines for the evaluation of results of conductive hearing loss, patients can integrate into social life without hearing aids): 26.5% pre-op and 35.3% post-op. $PTA \leq 50$ dB (mild hearing loss): 44.1% pre-op and increased to 70.6% post-op.

Improvement of ABG: ABG efficiency 6.5 ± 13.5 dB is not high in functional surgery but is good at CWD mastoidectomy. Moreover, ABG 30.6 ± 11.1 dB pre-op is not easy to improve so $24,0 \pm 9,8$ dB post-op is relatively good.

Looking at table 6, no case with $ABG \leq 10$ dB, ABG from 11 - 20 dB from 20.6% pre-op increase to 50% post-op. $ABG \leq 20$ dB (considered good) so over half of cases is successful tympanoplasty. $ABG \leq 30$ dB pre-op is 55.9% and post-op increase to 70.6%. Our hearing efficiency is

modest in comparing with Holt J.J's, equivalent with Minovi A.'s (42.9% ABG \leq 20 dB, 9.3% $>$ 30 dB), better than Zinis's (30.7% ABG \leq 20 dB).

- Hearing variation in tympanoplasty type IV and Eustachian clog up:

PTA's efficiency of type IV is 3.0 ± 10.8 dB, ABG efficiency is 0.2 ± 9.6 dB. Eustachian clog group have PTA and ABG are lower than pre-op that in turn -5.9 ± 24.3 dB and -8.4 ± 22.3 dB. Clog up the Eustachian tube equivalent to delete middle ear's anatomy, physiology and function. The improvement of PTA and ABG in type IV is trivial but in comparing with the clog up group we can see the hearing loss is better maintained, suggesting that the small cavity in hypotympanic maintain phase different operation between round and oval window. That is worthwhile indication even though more complex and slightly longer than clog up Eustachian.

CONCLUSION

1. Clinical, subclinical characteristics of dangerous chronic otitis media are done endoscopic transcanal canal wall down mastoidectomy

- **Clinical:** diagnosis is easy but difficult to define the limits.

+ **Functional symptoms:** almost otorrhea (94.7%) and earache (75.4%) but some have not characteristic of cholesteatoma (20.4% transparent fluid, 42.6% no fetid).

+ **Endoscopy:** suspicion lesion of cholesteatoma or grad IV of retraction pocket. The most is in the par flacida (94.7%) and attical wall (93%), the least at pars tensa (38,6%).

- **Audiotonal:** Most are conductive and mixed hearing loss (42.1% and 54.4%). Although 70% discontinued ossicular but ABG $<$ 35 dB (= 32.5 ± 11.6 dB).

- **CT Scan:** Very important in diagnosis and surgery.

+ **Diagnosis of dangerous chronic otitis:** Translucent blocks or hollow cavity limited to tympany – attic – aditus – antre with:

Bone erosion: attical wall 94.7%; ossicular chain 84.2%.

The complicational risks by opening: meningeal middle ear roof 17.6%, external semi-circular canal 12.3%, 2nd facial nerve 35.1%.

+ **Characteristics of mastoid and antre:** important for surgical indications.

Mastoid: compact (79%) or poor cell but compact in entrance (21%).

Small antre is advantage point for transcanal entrance: 8.8% without antre, 91.2% with antre; Antral size and ear canal: less than 51.9%, equal to 40.4%, slightly larger than 7.7%; The antral base is as higher than ear canal base as easier for surgery: 76.9% at 1/3 superior, 17.3% at 1/3 middle 5.8% at 1/3 inferior of extern ear canal.

Narrow mastoid entrance: lowered meninge 70.2% (below the middle ear ceiling 56.2%, close to ear canal 14%); TMB lie front 31.6% (equal with posterior antral wall 17.6%, lay front of 14%).

- **Anatomopathology:** some time difficult to take, 73,7% are cholesteatoma.

2. Results of endoscopic transcanal canal wall down mastoidectomy

- **Surgery process:** Despite have to operate by one hand but the small endoscope tip can flexibility put into the surgical field, the field of view is wider than the microscope, thus creating a complete CWD cavity to ensure control of lesions, drainage and tympanoplasty.

+ **Incision:** Mainstream is the inside ear canal but should coordinate the front ear to wider operative view and do "the meatoplasty out of cartilage".

+ **Opening attic-aditus-antre:** attical wall and postero-superior of ear canal is the safe drilling area.

+ **Lowering facial nerve wall:** use anatomy points and manipulation as the other entrance.

+ **Tympanoplasty** in 93%, clog up the Eustachian hole for 7%.

Eardrum reconstruction: cartilage or pericartilage 66%, ear canal skin – eardrum flap 32.1%.

Ossicular reconstruction: 35 ears, PORP 97.1%; 25.7% ceramic, 74.3% cartilage.

- **Postoperative:** good recovery with short time due to small cavity.

+ **Low complication rates:** 1 case facial paralysis (1.8%) recovered completely after a month.

+ **Less inflammatory secretion:** 77.2% dry ears, 22.8% less than 2 weeks.

+ **Shortest skin covering time:** average 5.44 ± 0.14 weeks (4 to 8 weeks).

- **Monitoring over a year:** N = 50, *average time* 35.1 ± 9.3 months ≈ 3 years.

+ **Functional symptoms improved:** no otorrhea and no earache; tinnitus and dizziness reduced.

+ **CWD cavity:** 82% stable, 18% with once inflammation.

+ **Eardrum:** most stable; 34.2% atelectasis grade I, II; 8.6% safe perforation.

+ **Cholesteatoma recurrence:** any case detected.

+ **Audiometry:** good results in hearing

Safe for inner ear: no difference of bone conduction pre and post-op 0.05 ± 8.2 dB.

Tympanoplasty type I, II, III (34 ears): PTA efficiency 5.3 ± 13.5 dB; PTA ≤ 20 dB (normal hearing): 8.8%; PTA ≤ 30 dB (mild hearing loss): 35.3%. The average ABG post-op: 24.0 ± 9.8 dB, ABG efficiency was 6.5 ± 13.5 dB, 50% good with ABG ≤ 20 dB, 70.6% good with ABG ≤ 30 dB.

Tympanoplasty type IV: PTA and ABG improve slightly but better than clog up Eustachian hole.

REQUEST

1. Dangerous chronic otitis cholesteatoma or grade IV retraction pocket have been indicated canal wall down mastoidectomy should use the endoscopic transcanal if CT Scan have some characteristics below: lesion reach to antre, compact mastoid or poor cell mastoid but compact in transcanal entrance and small antre.

2. To perform safety and efficacy of endoscopic transcanal canal wall down mastoidectomy, surgeon needs to update the knowledge of ear and mastoid anatomy and to practice techniques of ear endoscopic surgery (use instrument with one hand).

3. In general, in the canal wall down mastoidectomy and endoscopic transcanal canal wall down mastoidectomy if the hypotympanic cavity (including round windows) clean, Eustachian hole open should use the type IV instead of clog up the Eustachian tube because of better hearing performance and still safe.