

## CHARACTERISTICS OF WHITE MATTER HYPINTENSITY IN NORMAL COGNITIVE VIETNAMESE ADULTS USING MRI

Tong Quoc Dong\*, Vu Khac Quy\*, Le Gia Vinh\*\*,  
Tran Hai Anh\*, Nguyen Le Chien\*

### ABSTRACT.

**Objectives:** access the white-matter hypointensity (WMHypo) volume characteristics in relationships with age. **Methods:** Analysing for volumes of cerebral WMHypo volumes from cranial magnetic resonance images taken from 455 normal cognitive Vietnamese subjects (males 47,03%), and ranging in age from 17 to 87 years. **Results:** The volumes of WMHypo were increasing with age in both male ( $p < 0,001$ ) and female ( $p < 0,001$ ). And regression analyses indicated that WMHypo volume increasing in cubic manners that relatively stable with age under 40-50 y.o then sharply increase from 60s. **Conclusion:** White matter hypointensity had appeared since youth and boosted from middle age, since any cognitive impairment could be detected as in elders, and and its growth rate coexists with atrophy in the cerebral degeneration process such as Alzheimer and Parkinson diseases.

**Key words:** *White-matter lesions, magnetic resonance imaging*

### I. INTRODUCTION

The cerebral white-matter (WM) contains fiber pathways that convey axons linking cerebral cortical areas with each other and with subcortical structures, facilitating the

distributed neural circuits that subserve sensorimotor function, intellect, and emotion [1]. Mild and/or chronic vascular insult is an important biomarker for cognitive impairment [3] where damage accumulates silently for decades before the onset of clinically identifiable dementia symptoms [4]. Early detection of traces from microvascular disease is therefore critical to identify and guide efforts to prevent the onset of dementia [5]. Age-related white-matter (WM) lesion are considered as manifestation of small vessel disease and are a risk factor for stroke, cognitive decline and dementia and are mainly affect information processing speed and executive function [1]. The prevalence of WM lesion increases with age, that could account for 51% of randomly selected healthy subject aged 44-48 [2] and all had WMHypo in the age range 60-64 [6] but the prevalence and severity in younger asymptomatic population is less well studied.

In magnetic resonance (MR) imaging, white matter hypointensities (WMHypo) in T1 weighted images, and white matter hyperintensities in T2 weighted and FLAIR images are often encompassed lateral ventricles and are regarded as visualizations of WMHypo. Several automatic volumetry methods have been developed for WMHypo classification and Freesurfer is one of them and it contains automatic assessment of neuroanatomical subregional volumetry and has been shown to be comparable in accuracy to manual labeling for many tasks [7]. This research

\*Vietnam Military Medical University

\*\* Vietnam Medical Association

**Responsible person:** Nguyen Le Chien

**Email:** chien\_nguyenle@vmmu.edu.vn

**Date of receipt:** 30/6/2021

**Date of scientific judgment:** 31/7/2021

**Reviewed date:** 19/8/2021

analyzed MRI taken from normal cognitive Vietnamese to access the WMHypo volume characteristics in relationships with age.

## II. METHODOLOGY

### 1. Subjects and research design

MR images were taken from 455 righthanded, normal cognitive Vietnamese adults (214 males, age range 19-82 and 241 females, 17-87 year-old), who visited the outpatients ward at 108 Military Central Hospital from Nov. 2017 to Nov. 2018 for health issues not including neuropathy reasons.

They had no history of neuro-psychiatric disorders or chronic diseases, and had informed consent to participate in the study. Image data analysis and processing were performed at Department of Physiology, Vietnam Military Medical University.

### 2. Methods

The research has been conducted with convenience sampling. Three-dimensional brain scans were taken by a 1.5 Tesla MRI scanner system (Siemen, Germany), using the T1-weighted sagittal sequence with parameters: slice thickness 1 mm, TR = 15 ms, TE = 5 ms, NEX = 1 ms, flip angle = 30°, 25 x 25 cm FOV; matrix = 256 x 256, with more than 300 contiguous slices on each subject. Brain image scans were then reviewed and confirmed by specialist physicians that of subjects having no damages of central nervous system. The imaging data were stored in DICOM format, compressed to NIFTI, rendering and analysing for brain regions using FreeSurfer software version 6.0.0 [5]. Volumetric values (mm<sup>3</sup>) of the cerebral white-matter hypointensity were taken into account.

### 3. Data analysis

In the analysis of WMHypo volume changing with ages, subjects were categorized by gender and divided into 6 groups of age ranging from 17 to 87 years old. The volumes of cerebral WMHypo were compared among age groups within sex by a co-variance analysis (ANCOVA); the differences in age and the proportion of subjects among groups were compared using the Student's t-test and proportional comparisons (Chi-square tests). The analyses were made with SPSS 22.0 (IBM Inc., USA) and a significant difference was set as p value of less than 0.05.

## III. RESULTS

### 1. Subjects demography

The demography of 455 participants was similar to that of our reports [8], [9]. In short, there were no significant difference in gender proportion (214 male - 47.03% and 241 female - 52.07%,  $p = 0,21$ ) and mean age (male  $45,57 \pm 14,04$ ; female  $44,62 \pm 12,25$ ;  $p = 0,44$ ) of subjects. And the proportions of gender among age groups were statistical difference ( $p = 0,012$ ) could be attributed to the variety in the proportions of males and females among age groups of 45-54 and from 65.

In neuromorphology analysis, the difference in intracranial volume between genders would have certain effects on the size and volume of internal brain structures. Therefore, in evaluation of the WMHypo in this study, the estimated Total Intracranial Volume (eTIV) was regarded as a covariate factor.

### 2. White-matter hypointensity changed through age-group

White-matter hypointensity volumes of both genders in age-groups were presented in table 2 and figure 1 as follow:

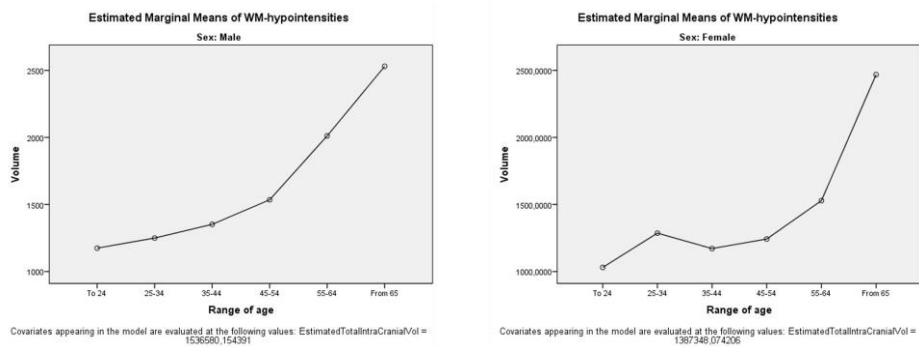
**Table 1.** White-matter hypointensity volumes in both genders

Age	Male ( $\bar{x} \pm SE$ )	Female ( $\bar{x} \pm SE$ )
To 24	1174,52 ± 151,88	1030,62 ± 131,66
25-34	1249,77 ± 84,63	1286,60 ± 53,82
35-44	1351,90 ± 82,78	1171,27 ± 51,35
45-54	1534,90 ± 87,57	1242,67 ± 45,56
55-64	2011,61 ± 85,58	1528,50 ± 56,91
From 65	2530,18 ± 121,10	2468,18 ± 137,89
F; p	$F_{(5,207)} = 23,34; p < 0,001$	$F_{(5,234)} = 19,09; p < 0,001$

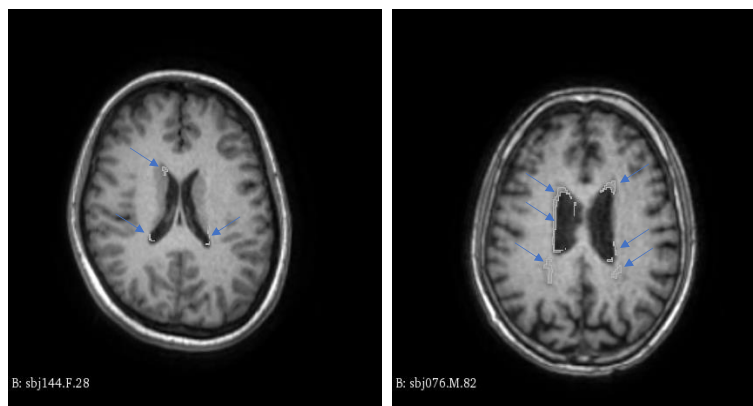
(Adjusted volume values with the eTIV were shown).

Data from table 2 expressed that the adjusted WMHypo volumes statistical significant accumulated a long with age ( $p < 0,001$  in either male and female). These changes were clearly plotted in the figure 2, that the WMHypo tended to initially

increased gradually from younger (under 24) to middle age then steapy (from 45-54 year-old) in both two sexes. Figure 2 illustrated the cerebral periventricular WMHypo in a youger and an elder, which WMHypo apparently accumulated higher in ageing.



**Fig 1.** WMHypo increased with age groups in Male and Female.



**Fig 2.** Periventricular white-matter hypointensity (arrows) appear dark in T1-weighted MRI from representative individuals. Automatically identified WMHypo are shown overlaid on anatomic coronal images with a gray mask in a 28 y.o woman (left) an 82 y.o man (right).

### 3. White-matter hypointensity equation

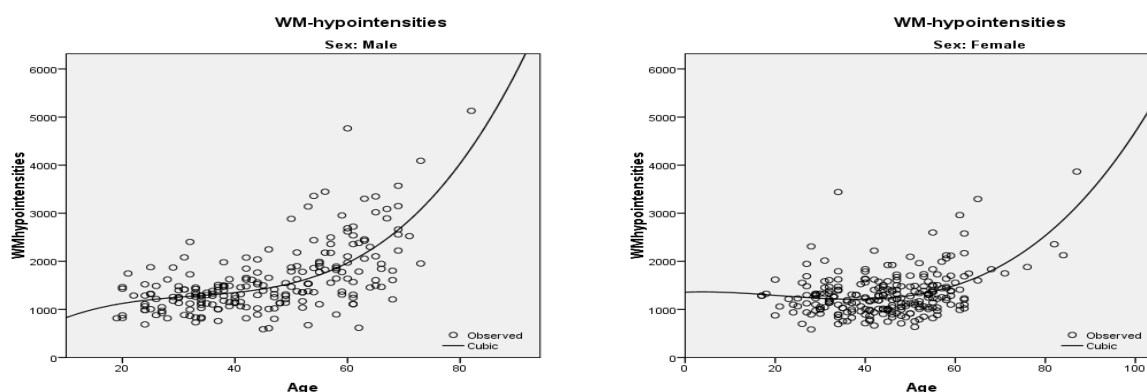
From results of age-related changes in WMHypo volume, we analyzed for the regression between WMHypo volume and chronological age. Relationships of

WMHypo volume with age were shown in table 2 and Figure 3. The positive WMHypo volume correlation with age were observed in both genders.

**Table 2.** Regression equations for the WMHypo volume by Age.

Gender	R <sup>2</sup>	p	Regression equation
Male	0,43	< 0.001	$0,02 \times \text{Age}^3 - 2,15 \times \text{Age}^2 + 78,75 \times \text{Age} + 235,70$
Female	0,235	< 0.001	$0,008 \times \text{Age}^3 - 0,49 \times \text{Age}^2 + 3,39 \times \text{Age} + 1358,89$

The results in Table 2 showed that in both genders, the WMHypo increased with age in a cubic manner (man: R<sup>2</sup> = 0,43, p < 0,001; woman: R<sup>2</sup> = 0,235, p < 0,001). As expressed in the Figure 3, the WMHypo volume remain relatively stable under 40-50 y.o then sharply increase from 60s.



**Fig 3.** Plots of WMHypo volume regression with age in Male (left) and Female (Right). The solid lines correspond to the quadratic regression equations; “o” symbols are observed values.

#### IV. DISCUSSION & CONCLUSION

The main finding of this study was that WMHypo had appeared since youth and boosted from middle age, since any cognitive impairment could be detected as in elders.

According to Schmahmann et al (2008), MRI has great sensitivity and reveals WM lesions that appear as white-matter hypointensity (on T1-weighted) as well as white-matter hyperintensity (on T2-weighted and FLAIR) [1]. Even these features are not

diseases specific because they just reflect an increased concentration of water within the affected tissue. The most common cerebral small vessels pathologies associated with WM lesion are related to hypertension, diabetes, atherosclerosis, and cerebral amyloid angiopathy. In ageing studies, multiple evidences suggest that vascular pathology is the main cause of most of the age-related WM lesions, and that there was an association between WM lesions and

cognitive dysfunction but only a amodest amount of variance in cognition performance is explained by WM lesion [1]

Wen et al. (2009) conducted a study in 218 subjects with WMHypo in comparison with 210 subjects without. In which, the periventricular “rim” and frontal and occipital “caps” of WMHypo were not taken as WMHs [2]. Authors found the high prevalence of WMHypo in asymptomatic individuals below the age of 50, with nearly one in two individuals so affected [2].

The pathological significance of WMHyps that are strictly peri-ventricular, comprising pencil-thin rims and caps has been questioned, and they have been often regarded as normal variants [2] but from our study, the early identified of WM lesion since youth and the increasing volume of WMHypo in strongly association with age in both sexes indicated that the WMHypo may occur early and its growth rate coexists with atrophy in the cerebral degeneration process such as Alzheimer and Parkinson.

REFERENCES

1. **Schmahmann JD, Smith EE, Eichler FS et al. (2008)** Cerebral white matter: neuroanatomy, clinical neurology, and neurobehavioral correlates. *Annals of the New York Academy of Sciences*, 1142:266-309.
2. **Wen W, Sachdev PS, Li JJ et al. (2009)** White matter hyperintensities in the forties: their prevalence and topography in an

epidemiological sample aged 44-48. *Human Brain Mapping*. 30(4):1155-1167.

3. **Gorelick PB, Scuteri A, Black SE, et al. (2011)**. Vascular contributions to cognitive impairment and dementia: a statement for healthcare professionals from the american heart association/american stroke association. *Stroke*, 42(9), 2672-2713.
4. **Brown WR, Thore CR (2011)**. Review: Cerebral microvascular pathology in ageing and neurodegeneration. *Neuropathology and Applied Neurobiology*, 37(1), 56-74.
5. **Wei K, Tran T, Chu K, et al. (2019)** White matter hypointensities and hyperintensities have equivalent correlations with age and CSF  $\beta$ -amyloid in the nondemented elderly. *Brain Behav.*, 9(12):e01457.
6. **W. Wen and P. Sachdev (2004)**. The topography of white matter hyperintensities on brain MRI in healthy 60- to 64-year-old individuals,” *NeuroImage*, 22(1):144-154.
7. **Olsson E, Klasson N, Berge J, et al. (2013)**. White Matter Lesion Assessment in Patients with Cognitive Impairment and Healthy Controls: Reliability Comparisons between Visual Rating, a Manual, and an Automatic Volumetrical MRI Method-The Gothenburg MCI Study. *J Aging Res.*, 2013:198471.
8. **Dong TQ, Chien NL, Truong DT, et al. (2019)** Measuring the corpus callosum and intracranial volumes of vietnamese normal adults using MRI. *J Military Pharmaco-Med.*, 6: 128-134.
9. **Dong TQ, Chien NL, Truong DT, et al. (2019)** Age, gender and brain and its ventricular volumes on magnetic resonance imaging in vietnamese adults. *Vietnam Med J.*, 483: 60-66.