



# Halofuginone Prevents the Progression of Osteoarthritis

## Citation

Khoynezhad, Shirin. 2015. Halofuginone Prevents the Progression of Osteoarthritis. Doctoral dissertation, Harvard School of Dental Medicine.

## Permanent link

<http://nrs.harvard.edu/urn-3:HUL.InstRepos:17331948>

## Terms of Use

This article was downloaded from Harvard University's DASH repository, and is made available under the terms and conditions applicable to Other Posted Material, as set forth at <http://nrs.harvard.edu/urn-3:HUL.InstRepos:dash.current.terms-of-use#LAA>

## Share Your Story

The Harvard community has made this article openly available.  
Please share how this access benefits you. [Submit a story](#).

[Accessibility](#)

***Halofuginone prevents the progression of osteoarthritis***

A Thesis Presented by

***Dr. Shirin Khoynezhad***

to

The Faculty of Medicine in partial fulfillment of the requirements for

the degree of

**Doctor of Medical Sciences**

*Research Mentor:*

*Malcolm Whitman*

*Professor*

*Department of Developmental Biology*

Harvard School of Dental Medicine Boston, Massachusetts

*February 2015*



© 2015 By Shirin Khoynezhad

All rights reserved.

## **COPYRIGHT STATEMENT**

---

“The author of a work holds the copyright, including the right to control the duplication, distribution, performance, display, and publication of the work. This was true of thesis, dissertations, and other works that were submitted to fulfill degree requirements. When a copy of a student's thesis or dissertation was deposited in the Countway Library, the student may wish to provide the Library with a non-exclusive right to reproduce the work, in whole or in part, for research and scholarly use.”

## **ACKNOWLEDGEMENTS**

---

“This thesis is dedicated to my family, for their endless love and support, and to all the individuals whom I learned from and helped me to have a productive, rewarding and enjoyable four years of residency at Harvard School of Dental Medicine. “

## TABLE OF CONTENTS

---

Abstract.....	7
Introduction and Review of Literatures. ....	9
I. Osteoarthritis	
a. Overview.....	9
b. Pathogenesis.....	10
c. Etiology and risk factors.....	23
d. Current treatments.....	24
e. Osteoarthritis in Temporomandibular joint.....	26
f. Osteoarthritis animal models.....	28
II. Halofuginone .....	32
Hypothesis and Specific Aims .....	37
Significance and Innovation.....	38
Materials and Methods .....	39
Results.....	52
Discussion.....	59
Conclusions.....	64
References.....	65

## ABSTRACT

---

**Background:** Halofuginone (HF) is a natural product that has been shown to have therapeutic benefits in a variety of pathologic conditions, from cancer to autoimmune diseases. These beneficial effects are mainly through inhibition of pro-inflammatory cytokines. Inflammatory cytokines have been recently shown to exert a crucial role in development of osteoarthritis and one of their most important targets is Matrix metalloproteinase-13 (MMP-13). In this preclinical study, we investigated the effect of HF on the progression of Osteoarthritis.

**Methods:** The effect of adding HF  $\pm$  IL-1 $\beta$ /TNF- $\alpha$  on mRNA expression of MMP-13 on the C28/I2 Chondrocytes was evaluated with qPCR *in vitro*. To study the effect of HF *in vivo*, a mice destabilization of the medial meniscus (DMM) osteoarthritis model was employed and untreated control group were compared with early treatment with HF (starting 48 hours post-surgery for 12 weeks) and late treatment (4 weeks post-surgery for 8 weeks). After sacrificing the animal, joint destruction in the knee tissue was assessed with Safranin O/Fast Green staining and MMP13 expression was evaluated by immunohistochemical staining.

**Results:** In chondrocytes, MMP-13 expression was significantly increased with IL-1 $\beta$  or TNF- $\alpha$  (13.77-fold, p-value<0.05 and 5.8-fold, p-value<0.05, respectively). Addition of HF Significantly reduced MMP13 expression close to baseline levels (1.73-fold, p-

value<0.05 when co-incubated with IL-1 $\beta$  and 1.6-fold p-value<0.05 when co-incubated with TNF- $\alpha$ ). Injection of HF in the mice osteoarthritis model *in vivo*, significantly reduced Osteoarthritis progression according to OARSI scoring (3.8 vs. 1.16 vs. 1.07, p-value<0.05) and there was no difference between early vs. late administration of HF. While MMP-13 was overexpressed in the control (DMM surgery without HF treatment) groups in IHC staining, expression of MMP13 was suppressed by injection of HF in both groups.

**Conclusion:** Halofuginone inhibits MMP-13 expression and diminishes joint destruction. These preclinical findings provide supporting data for clinical investigation of HF as a therapeutic target for osteoarthritis.

**Keywords:** Osteoarthritis, Halofuginone, MMP-13, Knee Joint, TMJ

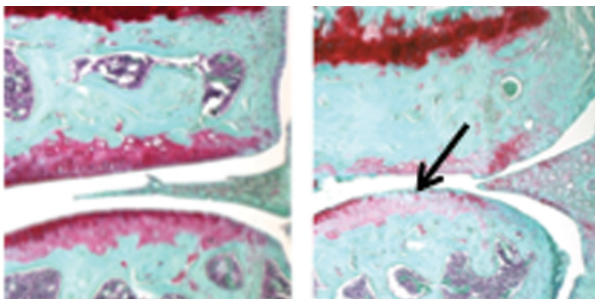
## INTRODUCTION and REVIEW OF LITERATURE

---

### I. Osteoarthritis:

#### *a. Overview*

Osteoarthritis (OA) is the most common type of arthritis and musculoskeletal condition with a significant health and social burden and one of the main causes of disability worldwide. It is caused by destruction of articular components, which leads to the functional failure of synovial joints (1-3) (Figure 1). Over 70% of Americans above the age of 55 are affected by OA, which mainly influence knees, hands, hips, spine and Temporomandibular joint (TMJ) (4-6). It starts with joint pain accompanied by different degrees of limitation in the range of motion and reduced quality of life. Due to the increasing longevity of life and obesity in the world, the destruction caused by OA rapidly grows which influence life quality of the affected individuals, which has also enormous costs to the health care system.



**Figure 1:** Destruction of cartilage in an Osteoarthritic joint (Right image, pointed by Black arrow) compared to an intact cartilage in a healthy joint (Left image)

### ***b. Pathogenesis***

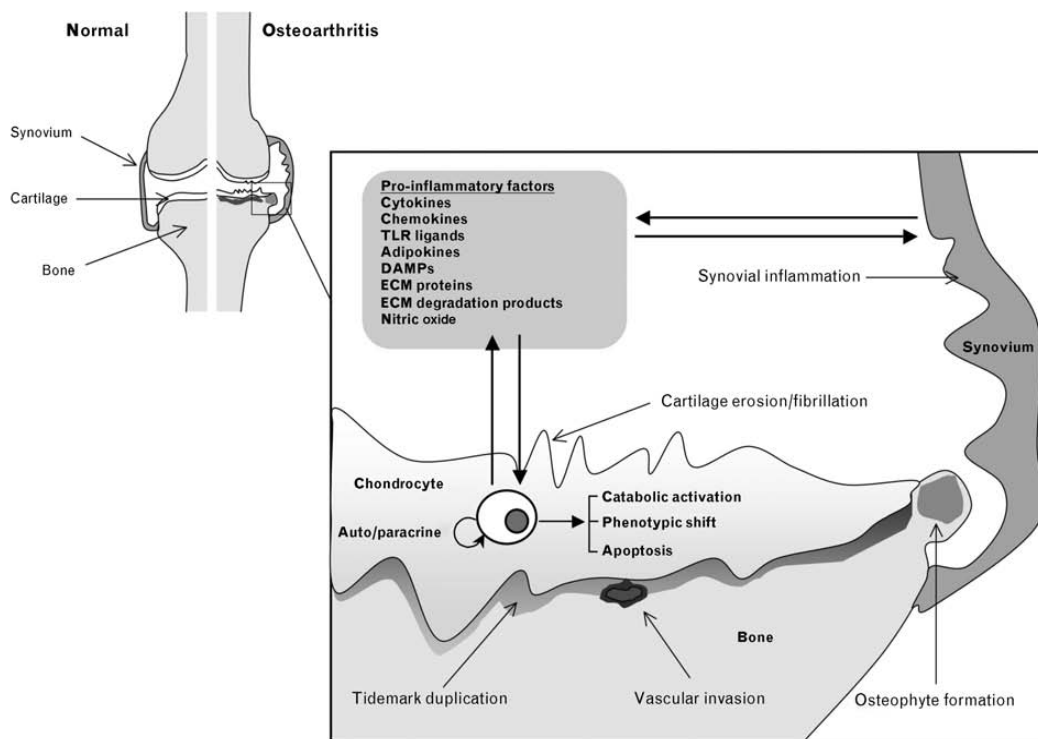
OA is a total joint disease that leads to loss of articular cartilage, peri-articular bone, synovial joint lining, the supporting connective tissue, and osteophyte formation (1, 2, 5, 7, 8). Adult articular cartilage is avascular, and its cellular components are chondrocytes, which has low turnover replacement of the extracellular matrix (ECM). Chondrocytes are specialized mesenchymal cells that are responsible for synthesis and repair of cartilage matrix (9). Articular chondrocytes can respond to direct biomechanical stress by increasing the synthetic activity and/or up-regulation of the inflammatory cytokines and they are believed to be the central players of osteoarthritis (10).

In a healthy joint, chondrocytes maintain the matrix components in a low turnover condition as opposed to an osteoarthritic joint where chondrocytes, alongside the other cells in the synovium, get activated due to exposure to abnormal insults, like high magnitude mechanical stress, inflammatory cytokines or different amount of matrix proteins and degradation products (11-13). After initiation of the disease, the pathological changes in OA follows a consistent pattern, which is chondrocyte clustering subsequent to up regulated cell proliferation, which in turn increase the general synthetic activities including ECM, expression of degradative proteinase genes, loss of proteoglycans and collagen type II degradation (14, 15).

OA is characterized by significant alterations in the composition, structure and function of the articular cartilage. Besides metabolic imbalance, up regulation of the whole



endochondral ossification process is an important determinant of OA progression, which starts with cell proliferation toward articular chondrocyte hypertrophy and apoptosis. To understand the pathophysiology of OA, it is critical to extend our knowledge of how abnormal biomechanics impact articular integrity and chondrocyte pathobiology (16) (Figure 2).



**Figure 2:** Biomechanical stress, leads to up-regulation of the synthetic activity and the inflammatory cytokines, chemokines, adipokines, Toll-like receptor (TLR) ligands, and other inflammatory mediators such as nitric oxide. The up regulation of cartilage-degrading proteinases by extracellular matrix (ECM) proteins and products can promote catabolic activation, phenotypic shift, and apoptosis.

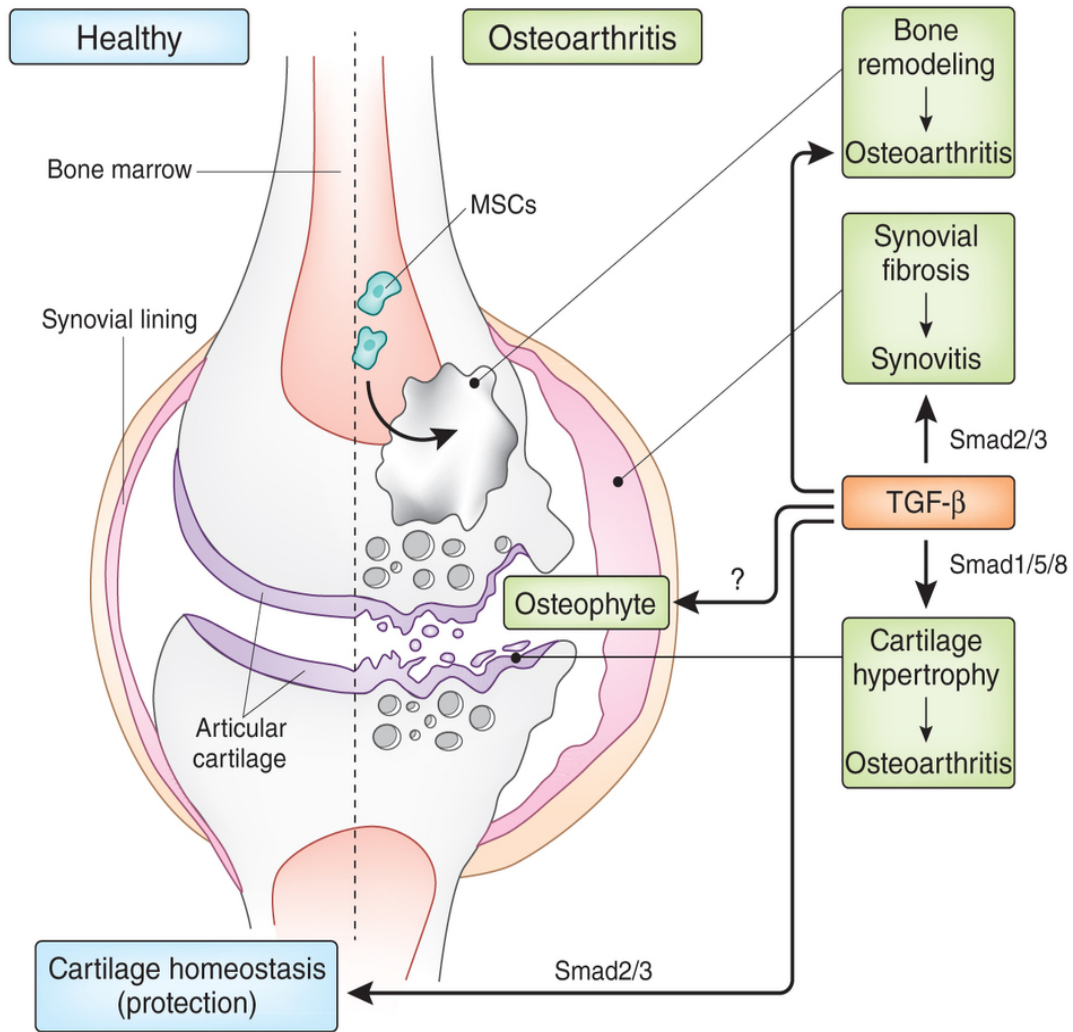
Osteoarthritis. *Current opinion in rheumatology*. 2011;23(5):471-8. Figure used with permission.

Chondrocyte differentiation is an important event in the development and progression of

OA. Transforming growth factor- $\beta$  (TGF- $\beta$ ) signaling pathway is a major regulator of chondrocyte differentiation and cartilage development, maintenance and repair and its alterations contribute to the pathogenesis of OA as well (10, 17-20). TGF- $\beta$  initiates chondrogenesis and chondrogenic condensation via activation of fibronectin synthesis and N-CAM regulation (21, 22). It also stimulates chondroprogenitor cell proliferation and differentiation through Smad3-dependent activation of SOX9 transcription (23). Smads are intracellular effectors of membrane-bound serine/threonine kinase receptors which is the main route of TGF- $\beta$  signaling. Modulation of receptor-Smads signaling is one important mechanism, through which TGF- $\beta$  signaling exerts its biological functions.

TGF- $\beta$  signaling can have a dual impact on chondrocyte differentiation. Chondrocyte terminal differentiation can be activated by TGF- $\beta$  signaling via the Smad1/5/8 route while it can be inhibited via the Smad2/3 route (24)

The controversial role of TGF- $\beta$  in regulating a chondrocyte's terminal differentiation is a result of differential activation of various Smad routes, which can have opposite regulatory effects on the terminal differentiation of chondrocytes. One suggested mechanism for development of osteoarthritis is a switch in TGF- $\beta$  signaling, from mainly Smad2/3 to dominant Smad1/5/8 signaling which alters articular chondrocytes and promotes progression of OA (10, 18, 25). It is anticipated that the role of TGF- $\beta$  signaling on chondrocyte differentiation can be modified by factors like mechanical loading, inflammation and aging (10, 17, 26, 27) (Figure 3).

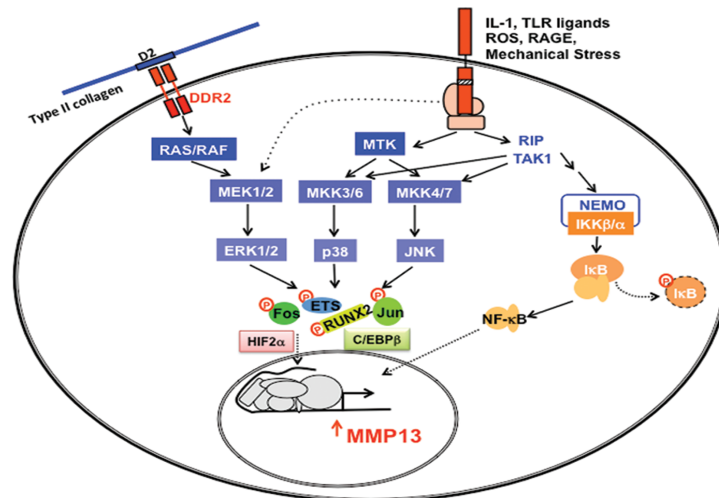


**Figure 3:** Effects of TGF- $\beta$  signaling on healthy and osteoarthritic cartilage

TGF- $\beta$  and osteoarthritis--the good and the bad. *Nat Med.* 2013 Jun;19(6):667-9. doi: 10.1038/nm.3228. Figure used with permission.

Chondrocytes have receptors for extracellular matrix (ECM) components which respond to mechanical overloading or trauma (28). Among these receptors, there are several

integrins, which are receptors for fibronectin and type II collagen fragments. Stimulation of these receptors activates the production of matrix degrading proteinases and inflammatory cytokines (29-33). Activation of inflammatory-induced and/or stress-induced signaling causes phenotypic shift, apoptosis and aberrant overexpression of inflammation-related genes and catabolic genes that play an important role in the pathogenesis of OA (12, 34-36). These signals stimulate the release of reactive oxygen species (ROS) that cause chondrocyte apoptosis and activation of stress induced kinases that promote production of several Metalloproteinases (MMP) especially MMP-13, nitric oxide synthase (NOS)-2, Cyclooxygenase (COX)-2 and a disintegrin and metalloproteinase (ADAM) (14, 31) (Figure 4).



**Figure 4:** Stimulation of receptors for type II collagen fragments activates the production of matrix degrading proteinases and inflammatory cytokines, which lead to release of ROS and production of MMP-13.

MMP-13 is the major enzyme that causes cartilage degradation and compared to other

MMPs, expression of MMP-13 is relatively restricted to the connective tissue (7, 37). Despite integrins, which bind to the collagen fragments, discoidin domain receptor 2 (DDR2) binds to collagen fibrils type II and X and subsequently stimulates its integral receptor tyrosine kinase. Activation of DDR2 in turn induces the expression of MMP-13 resulting in further cleavage of collagen type II (38-40). In other words, DDR2 is an additional receptor, which becomes activated by biomechanical triggers and subsequently leads to additional disruption of the peri-cellular matrix and activation of MMP-13 (41). MMP-13 not only causes irreversible joint damage in OA and promotes the progression of the disease, but more importantly also initiates the onset phase by causing the chondrocytes to leave their natural growth and differentiation arrested state (14).

Osteoarthritis have been considered as a non-inflammatory disease due to lack of neutrophil presence in the synovial fluid (42). On the other hand, some symptoms of the disease including pain, swelling, stiffness and loss of function of the joint show footprints of inflammation in the disease. Moreover, arthrocentesis from the osteoarthritic joints shows inflammatory cytokines, chemokines, and other inflammatory mediators traced in and can be measured in the synovial fluid of osteoarthritic patients (12),(43). (Table 1)

<b>Evidence</b>	<b>Observation</b>	<b>References</b>
<b>Clinical</b>	Effusion, Joint swelling or palpable synovitis Local signs of inflammation Sudden increase in pain Night pain and morning stiffness	Ayral et al 1999 (44) Krasnokutsky et al 2008 (45),
<b>Imaging</b>	Association between ultrasound-detected synovitis and clinical symptoms of synovitis Macroscopic synovial changes detected by arthroscopy in about half of patients with knee OA Gadolinium-enhanced synovium and increased synovial volume detected by MRI Correlation between MRI and histological observations Arthroscopic synovitis associated with progression of knee OA Synovitis seen using ultrasonography of symptomatic joints	Ostergaard et al 1997 (46), Fernandez-Madrid et al 1995 (47), Ayral et al 1999 (48), Loeuille et al 2005 (49), D'Agostino et al 2005 (50), Ayral et al 2005 (51) Keen et al 2008 (52),
<b>Histological</b>	Synovitis in the velocity of degenerative cartilage Infiltration of mononuclear cells (monocytes/macrophages, activated B cells and T cells) Synovial hypertrophy and hyperplasia Increased angiogenesis Adaptive immune T-cell and B-cell responses to fragments of extracellular matrix	Myers et al 1990 (53), Alsalamed et al 1990 (54), Nakamura et al 1999 (55), Shibakawa et al 2003 (56), Ayral et al 2005 (51), Walsh et al 2007 (57), Gobezie R et al 2007 (43), Sellam J et al 2010 (58), Maldonado M 2013 (59)
<b>Molecular</b>	Production and/or release of proinflammatory cytokines (TNF, IL-1 $\beta$ , IL-6, IL-8, IL-15, IL-17, IL-21) Increased activity of MMPs Increased production of PGE2 and nitric oxide Release of EGF and VEGF Production of adipokines Release of proinflammatory and pain neurotransmitters (substance P, NGF) Involvement of macrophages in osteophyte formation via BMPs	Smith et al 1997 (60), Furuzawa-Carballeda and Alcocer-Varela 1999 (61), Nissalo et al 2002 (62), Shibakawa et al 2003 (56), Farahat et al 2003 (63), Yuan et al 2004 (64), Benito et al 2005 (65), Presle et al 2006 (66), Brentano et al 2007 (67), Scanzello et al 2009 (68), Raychaudhuri and Raychaudhuri 2009 (69)
<b>Biological Markers</b>	Increased levels of MMP-13, MMP-3 and MMP-9 Increased levels of CRP (detected by ultrasensitive assay)	Conrozier et al 2000 (70), Masuhara et al 2002 (71), Pearle et al 2007 (72)

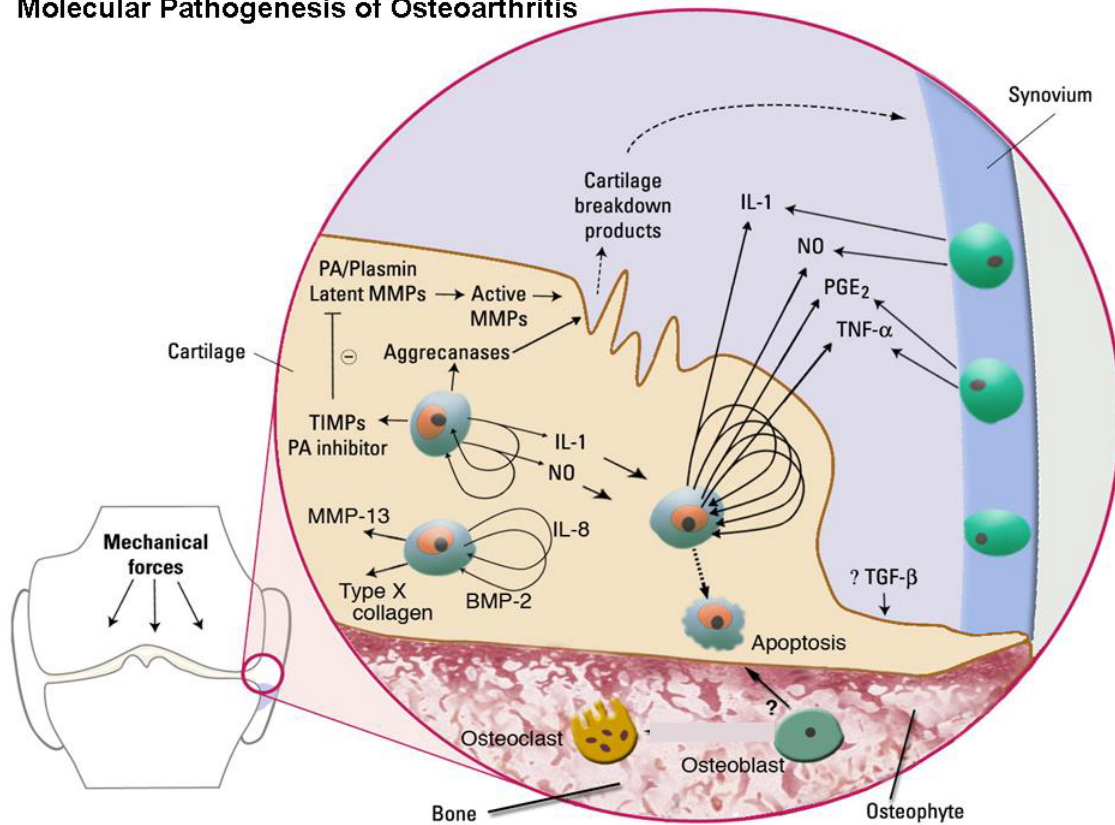
Table 1: Evidence of inflammation in OA

A growing list of studies now show that inflammation is the major factor in the progression of joint destruction, in addition to the signs and symptoms of the OA (58, 59, 73-78). Our current knowledge confirms that OA is initiated by both mechanical and inflammatory signals, activating similar signaling pathways and influences chondrocytes in a flawed attempt (31, 79-81).

Synovitis is common in the early stage and late stage of OA. This involves infiltration of mononuclear cells in the synovial membrane which accompanies with production of pro-inflammatory mediators like interleukin 1 $\beta$  (IL-1 $\beta$ ), tumor necrosis factor- $\alpha$  (TNF- $\alpha$ ) and various chemokines (58)

Non-traumatic cyclical loading of joints with appropriate magnitude can inhibit the induction of IL-1 that would initiate the cartilage matrix degradation (82). However, the impact of abnormal biomechanical stress on chondrocytes leads to expression of IL-1 at the concentrations which induce the expression of MMP-13, TNF-  $\alpha$ , and other catabolic genes. IL-1 $\beta$  and TNF- $\alpha$  also activate other pro-inflammatory cytokines like IL-6, IL-17 and IL-18, and chemokines like IL-8, which many of these factors promote the catabolic responses in chondrocytes (12) (Figure 5).

## Molecular Pathogenesis of Osteoarthritis

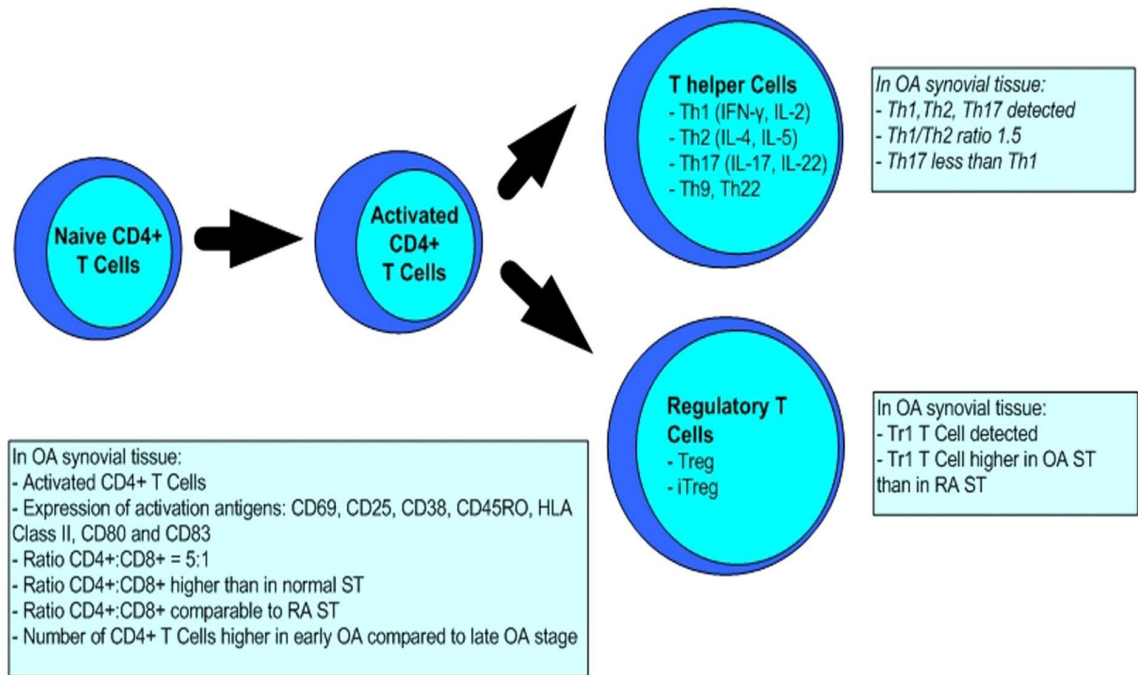


**Figure 5:** Molecular pathogenesis of osteoarthritis under mechanical stress. Nat Clin Pract Rheumatol. 2006 Jun;2(6):304-12. Figure used with permission.

Primitive CD4 T cells differentiate into different effectors and regulatory subsets to correlate immunity response, among them are  $T_H1$ ,  $T_H2$  effector subsets. These T cells, in turn, differentiate into pro-inflammatory T helper 17 (Th17) cells, which are also called tissue-protective induced T regulatory cells (83, 84). One important role for cytokines IL-1 $\beta$ , IL-23, IL-6 and TGF- $\beta$  is their influence on differentiation and maintenance of

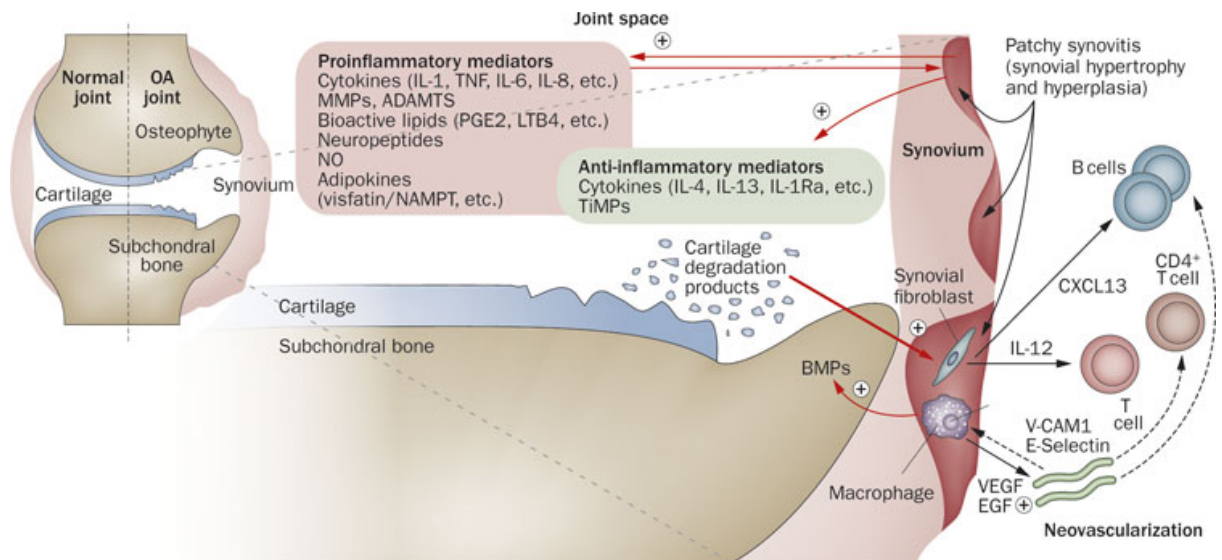


Th17 lineage (83-86) (Figure 6).



**Figure 6:** Th cells lineage (Th1, Th2 and Th17) , T regulatory (Treg) cells and induced T regulatory (iTreg) cells (Th3 and Tr1) in Osteoarthritis Osteoarthritis Cartilage. 2012 Dec;20(12):1484. Figure used with permission.

Th17 cells were initially introduced to contribute in the pathogenesis of autoimmune diseases, and later their significant role in other inflammatory processes, such those in infectious diseases was unravel (87-90) (Figure 7).

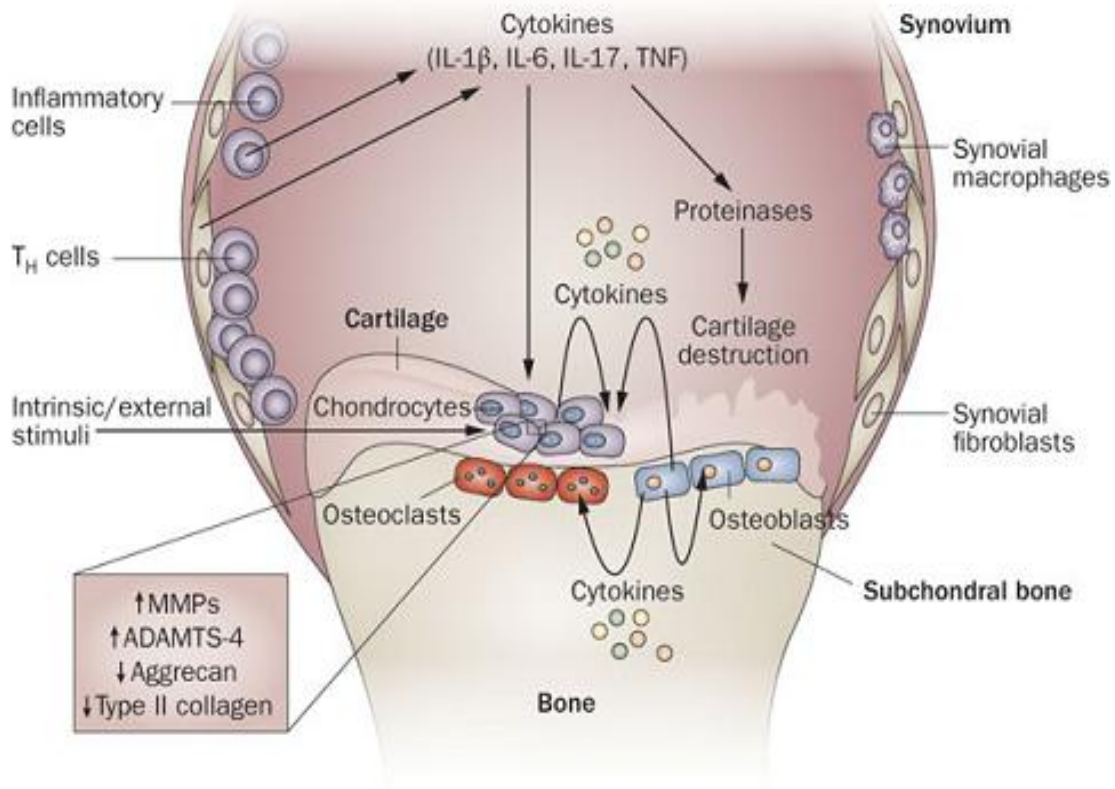


**Figure 7:** Involvement of the synovium in OA pathophysiology

The role of synovitis in pathophysiology and clinical symptoms of osteoarthritis. *Nat. Rev. Rheumatol.* doi:10.1038/nrrheum.2010.159. Figure used with permission.

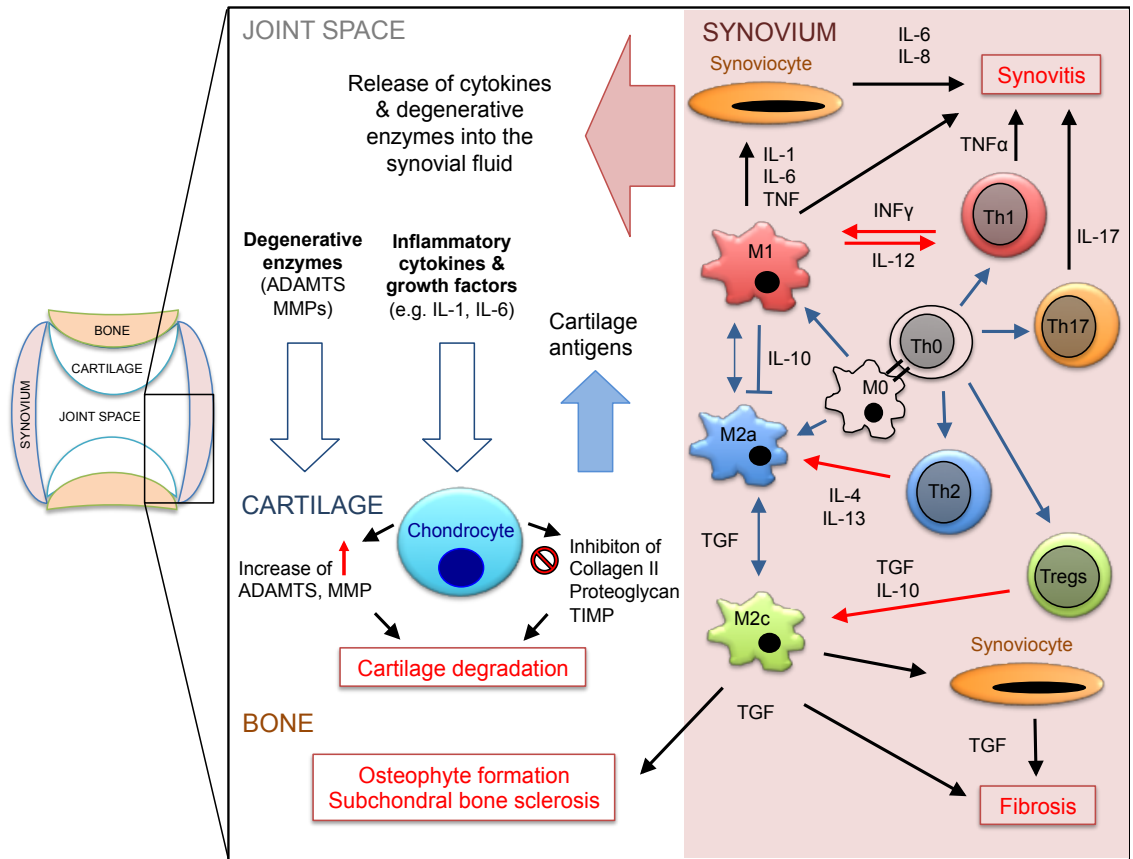
Th-17 cells produce pro-inflammatory cytokines, mainly IL-17, which activates other cytokines, chemokines and prostaglandins. Similar to rheumatoid arthritis (RA), the role of Th-17 in the pathogenesis of osteoarthritis has been recently suggested (Figure 8 and 9).

It has been shown that although there are quantitative differences in the number of Th17 cells between OA and RA, there is no qualitative difference between the expression of activation markers of Th17 cells between these two diseases (91).



**Figure 8:** The role of pro-inflammatory cytokines in the pathophysiology of OA.

Role of pro-inflammatory cytokines in the pathophysiology of osteoarthritis. *Nat Rev Rheumatol.* 2011 Jan;7(1):33-42. doi: 10.1038/nrrheum.2010.196. Epub 2010 Nov 30. Figure used with permission.



**Figure 9:** The role of Th17 in the Osteoarthritis

### ***c) Etiology and risk factors:***

Various risk factors contribute to the development of osteoarthritis. One is mechanical factors such as joint injury, occupational/recreational usage, reduced muscle strength, joint laxity and joint misalignment, all through the same mechanism: abnormal biomechanics either from mechanical trauma on a normal joint or a normal loading on a mal-positioned joint (12). Other factors include genetic factors and constitutional factors such as ageing, female sex, obesity and high bone density.

The articular surface has a critical role in transferring the load in the joint. There is strong evidence that certain conditions in which a higher load transfer or altered patterns of load distribution are produced can initiate and accelerate the development of OA (92)

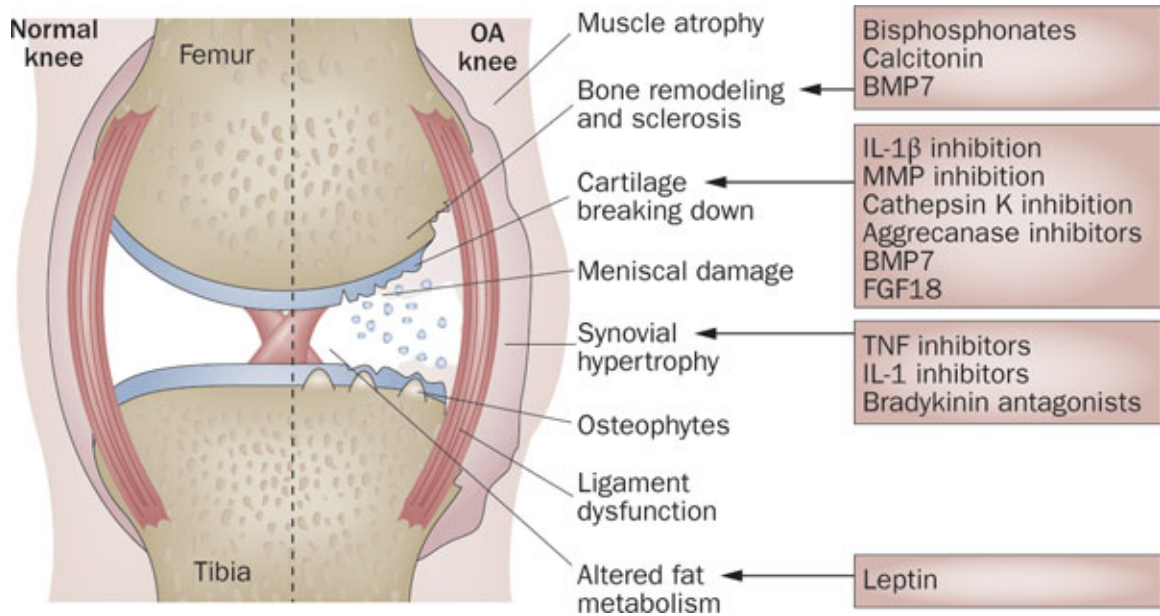
Studies from *in vitro* mechanical loading experiments show that traumatic static compression causes damage to the collagen network and down regulates the synthesis of cartilage matrix proteins, while dynamic compression up regulates the matrix synthetic activity (93). In response to trauma, the whole expression of inflammatory cytokines, stress response factors and cartilage-degrading proteinases are up regulated (36).

#### ***d) Current treatment***

Several modalities are currently practiced for symptomatic treatment of OA. Non-Pharmacological management of Osteoarthritis includes exercise and manual therapy, weight loss, electrotherapy, acupuncture, aids and devices and invasive treatments such as debridement and total joint replacements. Pharmacological management of osteoarthritis includes analgesics and anti-inflammatory drugs such as NSAIDs and COX-2 inhibitors, opioids and intra-articular corticosteroids injections.

Currently, there is no effective treatment of OA that can alter the progression of the disease. Current therapeutic regimens only provide symptomatic pain relief and do not have a major effect on the inflammatory process that leads to the progression of the disease. Since these drugs are not targeting the molecular processes responsible for the initiation and progression of the disease, there is no proven structure modifying therapy available to date (94).

Studies have shown that the pain and severity of the disease are associated with the synovitis (65, 95) and synovitis can be considered as a potential target for therapy in OA (58, 96) (Figure 10).



**Figure 10:** Pharmacologic therapies and the site of their impact.  
 Nat. Rev. Rheumatol. doi:10.1038/nrrheum.2010.178. Figure used with permission.

### ***e) Osteoarthritis in TMJ***

Most of the current understanding of cartilage degradation and OA is from large load bearing joints like the knee joint (97). In the field of prosthodontics, the temporomandibular joint (TMJ) is of large importance because reconstruction of the occlusion has a direct effect on the patient's TMJ. Like the knee joint, the TMJ is a complex synovial joint that has an articular disk and it is believed that cartilage degeneration process of the TMJ in OA follows a very similar pattern to that of the knee joint (98, 99). Their main difference is the type of cartilage that lines the articular surfaces. In the knee joint, the articular lining is hyaline cartilage, while in TMJ the lining is fibrocartilage (100).

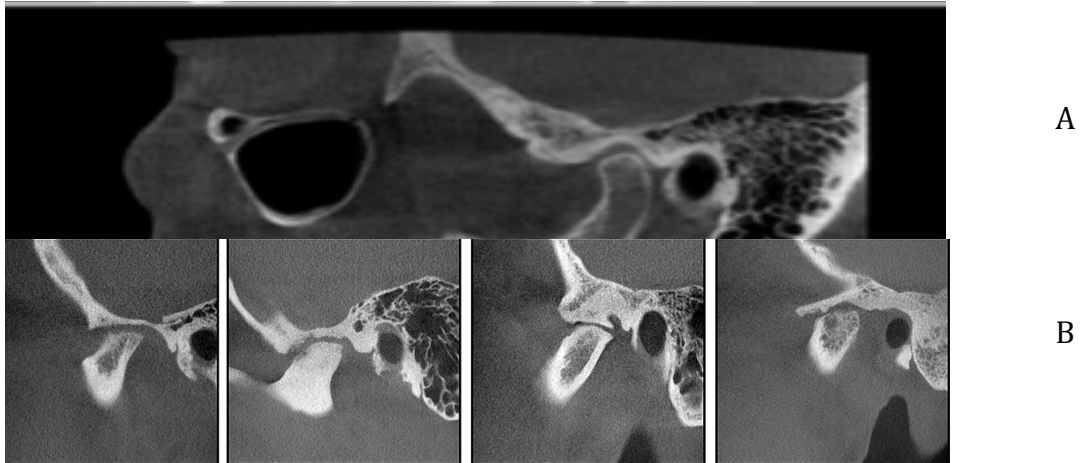
Temporomandibular disorder (TMD) affects a majority of the population as a myofascial dysfunction and degenerative joint disease, which is more common in women between the ages of 20-40 years old (101, 102). OA is the most common pathology of TMD (103).

Osteoarthritis of the TMJ is also a degenerative joint disease, which is age-related and is characterized by the continuous joint destruction of the articular tissues in the condyle of the mandible and glenoid fossa. Additionally, it has been shown that it is usually initiated with increased loading of the joint.

Signs of OA in TMJ include pain on palpation or pain during opening and lateral excursive movements with crepitation during mandibular movement (102, 104). Orthopantomogram or CT scans are usually used to evaluate the joint for any signs of



wear or osteophyte formation and to diagnose OA in TMJ (105) (Figure 11).



**Figure 11:** Osteoarthritic TMJs (B), CT-scan view, compared to the normal Joint (A). Dentomaxillofacial Radiology (2015) 44, 20140235 . Pictures used with permission.

Interestingly, in a comparison between OA in the knee joint and OA of TMJ, it was demonstrated that production of inflammatory cytokines like  $PGE_2$  is more significant in the TMJ compared to the knee joint, suggesting that inflammation may play a more significant role in pathogenesis of TMJ OA compared to the knee joint (100).

### ***f) Osteoarthritis animal models***

For better understanding of the disease, various animal models of OA have been established (106). The mice used for OA studies should have at least 10 weeks of age due to the fact that OA is a disease of adults and growing animals have a capacity to manage joint damage and at that age mice are mature skeletally. Generally, development of spontaneous OA is linked to a particular genetic background. For example, STR/ort mice spontaneously develop degenerative changes of knee joints with ageing, which is similar to human osteoarthritis.

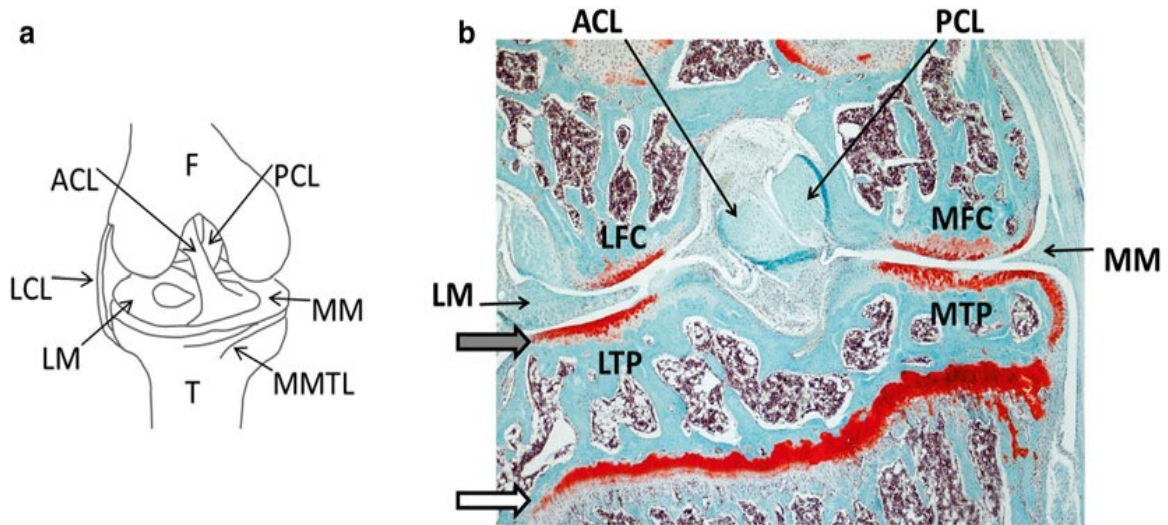
However, spontaneous OA models develop over a much longer period of the animal's life. Another method of creating an acute model for the study of OA is intra-articular injection of monosodium iodoacetate (MIA) or collagenase (107). However, it has some limitations. For example, due to the fact that MIA is a metabolic poison, there would be extensive death of chondrocytes in this model. Thus, application of this model is mainly limited to the induction of OA and it is mainly used for pain related Osteoarthritis research (108).

Mechanical instability-induced osteoarthritis mouse models have been established with a microsurgical technique to cause instability in the knee joints. This technique has been shown to be reproducible and the disease is very similar to human OA. Four slightly different methods have been developed which cause different grades of OA.

The partial medial meniscectomy (PMM) and medial collateral ligament transection (MCLT) models were the first surgical models of OA in the mouse (109). However, OA did not develop in the surgical knee and more severe OA was actually induced in the contralateral limb. This result could indicate that increased weight bearing was occurring in the non-operated limb (110). Visco et al (109) later hypothesized that mechanical instability created in the PMM and MCLT model could be too severe to overcome by the animal.

The two superior and more commonly used models of induced-OA in mice are the anterior cruciate ligament transection (ACLT) and destabilization of the medial meniscus (DMM). In the ACLT method(111) the first destructive changes in the mouse articular cartilage were a defect in the superficial zone evidenced by a decrease of Safranin-Orange (Safranin-O) staining, followed by a progressive cartilage destruction. These changes were very similar to human OA pathology recorded with arthroscopic and histological findings (111-113). Although instability was present in the whole knee joint, osteoarthritic changes were much more prominent in the tibial cartilage compared to the femoral condyle cartilage. This is due to the fact that tibial cartilage is much thinner and also osteophyte formation is very rare in the femoral condyle. For the same reason, current ACL models are more focused on OA changes in tibial cartilage (113).

In Figure 12 you can see an overview of the knee joint and the MMTL ligament which is transected to generate the generate destabilization of the medial meniscus (DMM) and the ACL is transected in the ACLT model (114).



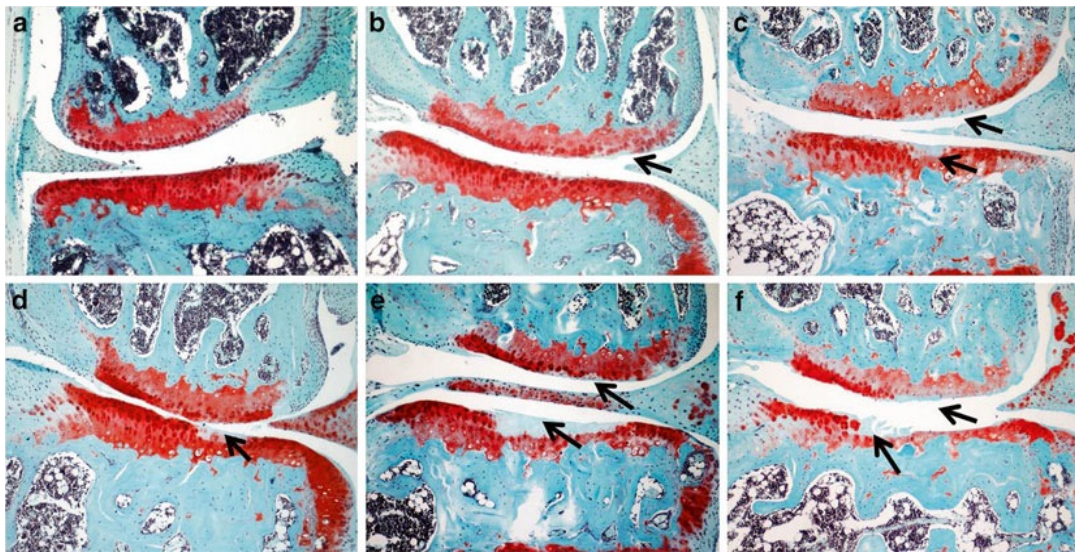
**Figure 12:** (a) Outline of a right knee joint. The MMTL is transected to generate destabilization of the medial meniscus (DMM) and the ACL is transected in the ACLT model. (b) Overview of Safranin-O stained of a mouse knee joint 4 weeks after DMM induction. *Grey arrow* indicates articular cartilage, *white arrow* indicates growth plate.  $\times 40$  magnification. ACL: anterior cruciate ligament; F = femur; LCL = lateral collateral ligament; LFC: lateral femoral condyle; LM = lateral meniscus; LTP: lateral tibial plateau; MFC: medial femoral condyle; MM: medial meniscus; MMTL = medial meniscotibial ligament; MTP: medial tibial plateau; PCL: posterior cruciate ligament; T = tibia .

Taken from Mouse genetics Methods and Protocols ISSN 1064-3745 , with permission.

DMM model has been used for induction of OA with great ease and reproducibility(114). Studies have been conducted to compare the severity of OA in both models of ACL and DMM surgery, aiming to identify a mild to moderate model of OA, in which the effects of disease modification in the knocked out mice would not be influenced by the severe biomechanical destruction associated with more severe models. Moreover, more severe models of OA have a great association with iatrogenic destruction, different biomechanical factors, or regenerative changes such as dramatic osteophyte formation or

ankylosis, which could make a false impression in the assessment of cartilage degradation.

The DMM model in these studies was completely reproducible and showed a slower mild to moderate osteoarthritic progression, which is very similar to the osteoarthritic changes in human. DMM model has been applied for evaluation of knocked out mice models in order to evaluate the impact of specific genes in the development of OA, its progression and severity (114-116) (Figure 13).

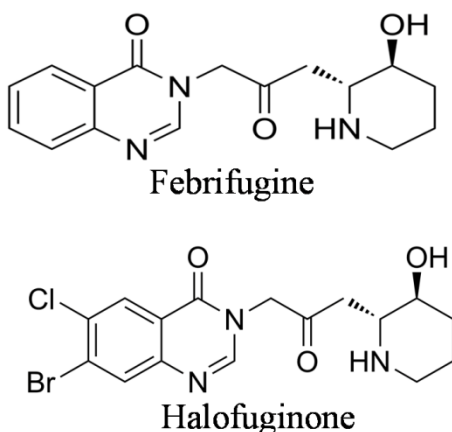


**Figure 13:** Osteoarthritis progression after DMM in wild-type mice. Osteoarthritis progression is demonstrated on medial areas of Safranin-O stained sections of right hind knee joints at 2 (b), 4 (c), 6 (d), 8 (e), and 12 (f) weeks after DMM surgery. (a) is the contra lateral joint. *Arrows* indicate articular cartilage damage of femoral condyle and tibial plateau. (a–f)  $\times 100$  magnification

Taken from Mouse genetics Methods and Protocols ISSN 1064-3745 , with permission.

## II. Halofuginone

Halofuginone (HF) is a small molecule that is analogue of Febrifugine, an alkaloid derivative isolated from *Dichroa febrifuga* plant (117). This plant has been used for treatment of malaria for centuries (118). Halofuginone [7-bromo-6-chloro-3-[3-(3-hydroxy-2-piperidinyl)-2-oxopropyl]-4(3H)-quinazolinone] (Figure 14) has been used in poultry centers (119, 120). It is also FDA approved additive for the animal's food for prevention of coccidiosis (121) and against protozoan parasites in cattle (122).



**Figure 14:** Chemical structures of Febrifugine and Halofuginone

Recently HF has attracted a lot of attention because of its broad beneficial biologic activities against a variety of diseases such as malaria, cancer and fibrosis related and autoimmune disorders (123-125).

HF exerts its biological functions through two distinct mechanisms: (1) inhibition of TGF- $\beta$  signaling pathway (124, 126) and (2) Anti-inflammatory responses through inhibition of Th17, as a result of inhibition of prolyl-tRNA synthesis and activation of



Amino Acid Response (AAR) pathway (127-129).

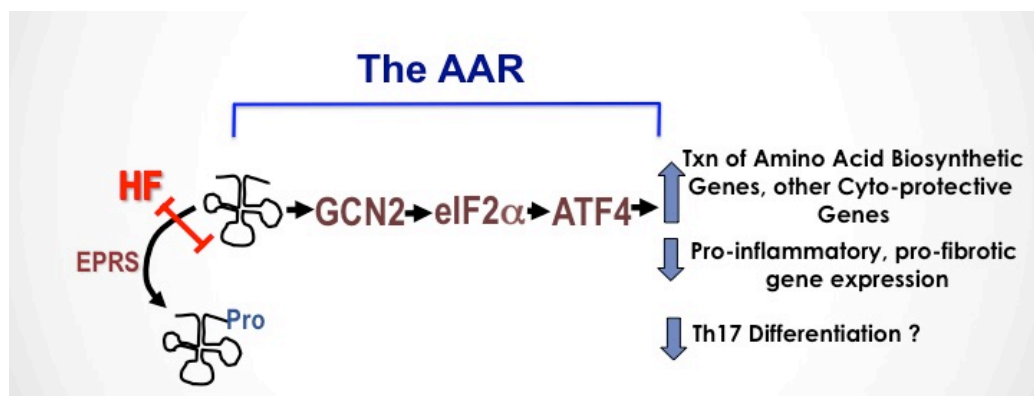
The crosstalk between these two mechanisms may be the TGF- $\beta$  pathway. Th17 differentiation in mice initiates with TGF- $\beta$ , IL-1 $\beta$  and IL-6. In humans, combination of TGF- $\beta$  and IL-21 initiates the differentiation of primitive T cells.

HF, *in vitro*, was shown to down regulate Smad3 protein (130), reduce the amplitude of TGF- $\beta$  dependent Smad3 phosphorylation and up regulate inhibitory Smad7 in fibroblasts, pancreatic and hepatic cells, myoblasts and tumor cells (131-135).

HF is an antifibrotic agent as well. Fibrosis is a result of chronic inflammation, which leads to destruction of organ's architecture and function. Altering TGF- $\beta$ , MMPs and the Tissue inhibitor of metalloproteinases (TIMPs) play an important role in the ECM regulation. The antifibrotic feature of HF was discovered by serendipity and later on explored further in animal models and in humans (117, 124, 126). *In vitro*, HF reduces the amplitude of collagen  $\alpha 1$  (I) gene expression in murine, avian and human fibroblasts derived from cornea (130) and *in vivo* in scleroderma and graft versus host disease (GVHD) patients (136). In animal models, when excess collagen was a characteristic of the disease, HF can inhibit the collagen synthesis (131, 137) and resolve the established fibrosis (138, 139). The ability of HF to resolve the pre-existing fibrosis is because of its ability to down regulate the collagen synthesis and at the same time, up regulates collagenase activity by increasing synthesis of TIMPs, which that regulates MMPs activity (138, 140, 141).

HF inhibition of ProRS activity leads to intracellular accumulation of uncharged tRNA and mimics the reduction of available cellular proline. This pathway requires ATP, which binds the 2 parts of HF on the human ProRS in a way that one part mimics proline attachment and the other part mimics the 3' end of tRNA (142).

Th17 cells regulate inflammation through its produced cytokines, mainly IL-17. IL-17 is a pro-inflammatory cytokine that stimulates other cytokines, chemokines and prostaglandins. HF down regulation of T-cell proliferation is correlated with up regulation of cell apoptosis and decrease in proline uptake, and shows the participation of amino acid starvation response (AAR) (128, 143, 144). This process takes place by activating the integrated stress response (ISR) which happens when cells experiencing metabolic, hypoxic or oxidative stress (145). HF activates the AAR by mimicking proline removal, and results in down regulation of inflammatory process (Figure 15).



**Figure 15:** AAR activation by HF inhibits prolyl tRNA charging enzyme EPRS results in uncharged tRNA accumulation. Uncharged tRNA activates the sensor kinase GCN2, leading to phosphorylation of eif2a and changes in translation and transcription of pro-inflammatory genes.



HF also has inhibitory effect on angiogenic cascade like prevention of endothelial cell MMP-2 expression and basement membrane invasion(146).

So far, HF has been studied in a number of clinical trials. It has been locally applied to the GVHD patients and has shown a significant decrease in collagen content without any systemic or local toxicity and no side effects (147). It has been used for AIDS related Kaposi sarcoma(148), in addition to a scleroderma trial, which revealed a statistically significant decrease in disease severity score (149).

HF has been also orally administered as a phase I clinical trial for patients with solid tumors and showed that therapeutically effective plasma levels can be reached without any toxicity. The minimum effective dose was 0.5 mg/kg and the maximum tolerant dose (MTD) was 3.5 mg/kg. The dose limiting toxicity (DLT) symptoms were vomiting, fatigue and nausea (150).

In a similar fashion to autoimmune and chronic inflammatory disease, therapeutic modulation of the tissue remodeling and invasive activities of cells could provide a powerful complementary approach to the inhibition of the pro-inflammatory activities of immune cells. Despite the previous dogma, we now believe that pathologic infusion of inflammation is a distinct characteristic of OA, which reflects failure of the immune system to restore tissue homeostasis. HF promotes restoration of immune homeostasis by inhibiting the differentiation and expansion of Th17 cells. Our research group at Whitman lab has also shown that HF can act directly on fibroblasts to prevent their

activation, inhibit chronic inflammation, and modulate pathologic tissue remodeling by activating the same target pathway (the AAR pathway) that is critical for immunomodulation (127, 145).

Inflammation plays an essential role in the pathogenesis of the osteoarthritis and preventing inflammation without inducing generalized immunosuppression would hypothetically be a great therapeutic strategy.

MMP-13 is interstitial collagenases that degrade type II collagen in cartilage and this is a committed step in the progression of OA (151). The expression of MMP-13 is regulated by inflammatory responses and is substantially increased in response to IL-1 $\beta$  and TNF- $\alpha$ . Elevated levels of these collagenases are observed in arthritic tissues including OA. Cytokine-mediated MMP-13 gene regulation plays a crucial role in the pathogenesis pathway and thus, it can serve as a potential therapeutic target for inflammatory processes of the joints i.e. osteoarthritis (152).

We hypothesize that HF can regulate the interplay between inflammatory activation and MMP13 expression, and subsequently through that, it can prevent MMP13 mediated joint destruction in OA.

## HYPOTHESIS AND SPECIFIC AIMS

---

- **Hypothesis:** HF prevents OA associated joint destruction and inhibit the progression of OA by down regulation of MMP13 expression
- **Specific Aim 1:** *To investigate the effect of HF on MMP-13 expression in chondrocytes during inflammation.*

CT-28I2 Human chondrocytes will be treated with HF both in the presence and absence of inflammatory cytokines and MMP-13 gene expression will be evaluated using q-PCR.

- **Specific Aim 2:** *To investigate the effect of HF on the progression of OA in Mice model.*

DMM OA-induced model is employed and animals are treated with HF. Progression of OA and expression of MMP-13 will be evaluated using Safranin O/fast Green and Immunohistochemistry staining, respectively. We will address whether timing of administration of HF (early after injury vs. late administration, 4 weeks after the injury) affects potential therapeutic efficiency of HF.

## **SIGNIFICANCE AND INNOVATION**

---

- **Significance:**

This is preclinical study that introduces a novel therapeutic approach for the treatment of OA and establishes a new paradigm for alleviating the destruction of joint that is driven by patho-physiologic inflammation.

- **Innovation:**

Currently, there is no treatment for OA, which can alter the progression of the disease. The existing pharmacological treatment for the mean time provides only symptomatic pain relief and have minor effect on the inflammation which leads to the progression of the disease since these drugs are not targeted to block the molecular processes responsible for the initiation and progression of the disease, so there is no proven structure modifying therapy available to date. Eventually, as the disease progresses, OA patients have to undergo total knee replacement as an end stage treatment. This will be the first preclinical study, which evaluates the effect of HF in the osteoarthritis, and can provide supporting data for further clinical investigations to develop a drug to prevent the progression of Osteoarthritis.

## METHODS AND MATERIALS

---

### ***In vitro:***

#### ✓ *Cell Culture:*

Immortalized C-28/I2 chondrocytes(153), were used for the *in vitro* studies. Ten percent pure HF was kindly provided as a gift by Hangpooon Chemical Co. (Seoul, South Korea). Then it was further purified via HPLC to >99% purity and used for the experiments.

Cells were seeded at  $3.5 \times 10^5$  cells per well and cultured at 37°C in 5% CO<sub>2</sub> in Dulbecco's modified Eagle's medium (DMEM)/Ham's F-12 medium supplemented with 10% fetal bovine serum (FBS) (Gibco, Gaithersburg, MD) and 1% Penicillin-Streptomycin (Gibco). Upon confluence, cells were split using 0.03% trypsin-EDTA and seeded at the same density. The second day after seeding, the media was changed to DMEM/F-12 with 0.2% FBS and 1% PS. In order to assess the effects of Halofuginone on MMP-13 expression *in vitro*, we added Halofuginone (200nM per well), IL-1 $\beta$  (10ng/ml) or combination of them and an equal volume of the vehicle DMSO to the 4th group as a control. On the third day, we added 200nM of Halofuginone and on the fourth day we added the IL-1 $\beta$  10ng/ml per well and 6 hours later we harvested the RNA for quantitative polymerase chain reaction (qPCR) assay.

To validate the findings with another inflammatory marker, we repeated this experiment and used TNF- $\alpha$  (10ng/ml) instead of IL-1 $\beta$  (Table 2).

<b>Groups</b>	<b>Day1</b>	<b>Day2</b>	<b>Day3</b>	<b>Day4</b>
<b>- HF - IL-1<math>\beta</math>/TNF-<math>\alpha</math></b>	10% FBS	1% FBS		
<b>+ HF - IL-1<math>\beta</math>/TNF-<math>\alpha</math></b>	10% FBS	1% FBS	+ 200 nM HF	
<b>- HF +IL-1<math>\beta</math>/TNF-<math>\alpha</math></b>	10% FBS	1% FBS		+10ng/ml IL-1 $\beta$ /TNF- $\alpha$
<b>+HF +IL-1<math>\beta</math>/TNF-<math>\alpha</math></b>	10% FBS	1% FBS	+ 200 nM HF	+10ng/ml IL-1 $\beta$ /TNF- $\alpha$

**Table 2:** Experimental conditions for qPCR experiments. Medium and supplements were added to the chondrocytes culture medium at the following concentrations: Halofuginone (200nM per well), IL-1 $\beta$  (10ng/ml)/ TNF- $\alpha$  (10ng/ml)

✓ *Quantitative real-time PCR:*

C-28/I2 chondrocytes were activated as described above, collected at the indicated times and cell pellets were flash-frozen in liquid nitrogen. Total RNA was isolated from cultured cells using RNeasy mini kits (Quiagen, Hilden, Germany) according to the

manufacturer's instructions. Afterwards the RNA samples were treated with DNase I (Sigma).

Sybrgreen quantitative real-time PCR was performed on RNA samples following reverse transcription via SuperScript II first-strand cDNA synthesis kit (Invitrogen). All qPCR data was collected on an iCycler thermal cycler (Bio-Rad). Quantitative real-time PCR was performed using primers for MMP-13. Primer sequences are listed below.

(5\_-CCAGTCTCC- GAGGAGAAACA-3\_ [forward] and 5\_-AAAAACAGCTCC-GCATCAAC-3\_ [reverse]) and GAPDH (5\_-GGTGAAGGT- CGGAGTCAACGGA-3\_ [forward] and 5\_-GAGGGATCTC- GCTCCTGGAAGA-3\_ [reverse])

PCR reaction was performed at 95 °C for 3 min followed by 50 cycles of 95 °C for 30 seconds, 60°C for 30 seconds, and 72°C for 30 seconds, with a final extension at 72°C for 4 min. A melting curve (temperature range between 55 and 95 °C with +0.5 °C intervals) was generated to test the specificity of the PCR product, at the end of the PCR cycles. A cDNA sample in each experiment was tested in triplicate and each experiment was performed two times. As an internal control, we used glyceraldehyde-3-phosphate dehydrogenase (GAPDH) gene. We tested the efficiency of PCR (standard curve) by plotting the amount of PCR product versus the known amount of a template, 0.001, 0.01, 0.1, 1, and 10ng. In theory, when the slope of the standard curve is -3.322, the efficiency of PCR is considered 100%. In our experiments, the efficiency reached 90% or higher.

## ***In vivo:***

### ✓ *DMM OA model:*

DMM injury-induced osteoarthritis model was used for the *in vivo* analyses of this study. Mice at the age of two months were anesthetized with Ketamine (100 mg/kg BW) and Xylazine (10 mg/kg BW) intra-peritoneally, and knees were prepared for aseptic surgery. Buprenorphine was provided peri-operatively at 0.09 mg/kg subcutaneously. After sedation, a bland ophthalmic ointment was placed in both eyes to prevent desiccation of the cornea. The criteria used to assess the level of anesthesia during the surgical procedure was respiration rate, muscular relaxation and toe or tail pinch. The level of consciousness was assessed every five minutes. Mice were clipped around the site of incision with an animal clipper. The clipped site was scrubbed with surgical disinfectants 10% Povidone-iodine three times and wiped with 70% alcohol. The joint capsule immediately medial to the patellar tendon was incised and opened with a #15 blade. To expose either the intercondylar region and providing visualization the meniscotibial ligament of the medial meniscus, a blunt dissection of the fat pad over the intercondylar area was performed. Then, The medial meniscotibial ligament (MMTL) was identified running from the cranial horn of the medial meniscus laterally into the anterior tibial plateau. Sectioning of MMTL with a #11 blade results in the destabilization of the medial meniscus (DMM). The MMTL anchors the medial meniscus (MM) to the tibial plateau, while the anterior cruciate ligament restricts the tibia from moving anteriorly, relative to



the femur. When MM is intact, there is more balance and area of contact between the articulating surfaces, providing a larger area to transfer the weight-bearing forces. Upon transection of the MMTL, the MM displaces medially, and weight bearing area will concentrate on a smaller area, leading to increased mechanical stress. Upon transection of the MMTL, the mechanical load on the knee joint is altered, which leads to increased mechanical stress so approximately 12 weeks post operation there is extensive articular cartilage degeneration in the surgical knee.

The joint's capsule was closed using a continuous 8-0 tapered Vicryl suture and for the subcutaneous layer we used 7-0 cutting Vicryl. The skin was closed by one or more sutures and triple antibiotic ointment was applied on the incision. For the post-surgery recovery period, the mice were placed on an electric blanket to prevent hypothermia. Mice were stimulated every 10 minutes. After they return to sternal recumbency and have regained the ability to control their airways, the mice were returned to their room and monitored continuously until they have recovered from anesthesia. Buprenorphine at 0.05 mg/kg was provided subcutaneously every 12 hours in first 48 hours post-surgery. We monitored post-operative animals within 3 hrs post-operation including respiration rate, muscular relaxation and toe pinch. Animals were monitored twice daily for four days following surgery. We recorded the care (including administration of analgesics) and monitoring in animals post-operatively with the Rodents Surgery Report (RSR). After 4 days post-operation, we used the Experimental Illness Report (EIR) to record the care and monitoring of experimental illness in animals.

There are no reports indicating that such surgery affects the health of the mice, their eating, drinking and joint movement and the mice undergone surgery develop early histological signs of OA by the time when they are euthanized at 12 weeks post-surgery (154).

However, we were aware that animals may develop some complications/impairment such as lameness, irritation and sluggish immediately post surgery. Additional care, such as food and hydrogel on a Petri dish placed on the bottom of the cage, were arranged to ensure that animals are able to reach food and water. In this case, the vet staff would be contacted or animals were humanely euthanized.

In addition, if the animals show any sign of infection in the surgical area, we would have treated them with antibiotics, such as Vetropolycin (bacitracin-neomycin-polymyxin ointment) applied on surgical area.

The animals used for this study didn't develop any complications or infection during the study.

Mice were kept in a virus-free animal facility at Harvard Medical School under a 12-hour lighting schedule (12 hours with light and 12 hours without light).

✓ *HF treatment:*

After the DMM surgery, we divided the animals into 3 groups, 6-7 mice per group and for Test 1 group we started the Halofuginone treatment with subcutaneous injections 2 days post DMM surgery (400 µg/kg diluted in 1ml PBS) every other day for 12 weeks. In the Test 2 group we started the Halofuginone treatment with subcutaneous injections 4 weeks post DMM surgery (400 µg/kg diluted in 1ml PBS) every other day for 8 weeks. The 3rd group served as the control group which they received 1ml PBS subcutaneous injections with the same intervals and pattern as their peer test groups.

✓ *Joint collection, processing and sectioning:*

12 weeks post DMM surgery all the mice sacrificed by CO<sub>2</sub> asphyxiation.

We displace the air in a suitable airtight container with CO<sub>2</sub> fed in from a compressed gas cylinder. We placed the animals gently in the container. We verified that the regulator has the correct psi (pounds per square inch), which is no higher than 5 psi. The flow rate should displace no more than 30% of chamber/cage volume per minute. Based on the guidelines, for a typical mouse cage this would be ~2 liters/minute. Unconsciousness occurs within 30 seconds, but animals were left in the container for several minutes to ensure death. We confirmed death by lack of cardiac pulse. We patiently waited approximately 3-5 minutes for the animal to stop moving or breathing. The Eyes should be fixed and dilated then we turned off CO<sub>2</sub> tank and the regulator valve to stop the flow of CO<sub>2</sub>.

All protocols and procedures were approved by the Institutional Animal Care and Use Committee (IACUC) at the Harvard University.

Then both left and right knee joints were harvested and prepared for sectioning and analysis. We dissected the knee joints and removed the skin and muscles. Sample tissues were fixed in 10% neutral buffered paraformaldehyde solution (VWR, Radnor, PA, USA) at the room temperature for 6 hours. Then they have kept in 4°C overnight, then we washed the samples with tap water every 30 min for 5 hours. Afterwards we decalcified them with 20% EDTA solution for two weeks and changed the decalcifying solution every two days. After 2 weeks we washed the joints with PBS for 30 mins. To check the efficacy of decalcification we did the neutralizing test with Cal-arrest (Decal Chemical Corp.). Then we dehydrate the specimens with ascending alcohol row (2–3 h EtOH 50 %, 2–3 h EtOH 70 %, over night EtOH 96 %, 4 h EtOH 96 %).

We removed the alcohol and solvent with 2-propanol (twice 2–6 h) afterwards. The specimens were then ready for embedding.

The samples were processed and embedded in paraffin at 60°C and the blocks cooled down at least for 24 hours when they were ready for sectioning. We cooled the paraffin blocks at 0°C for at least 30 min before sectioning.

Six- $\mu$ m-thick mid-sagittal sections at different levels were cut from the medial compartment of the joints. The sections were mounted on the slide and dried for at least 3 days at 37°C, then they were stained with safranin O/Fast Green (SO/FG).

✓ *Safranin O/Fast Green staining:*

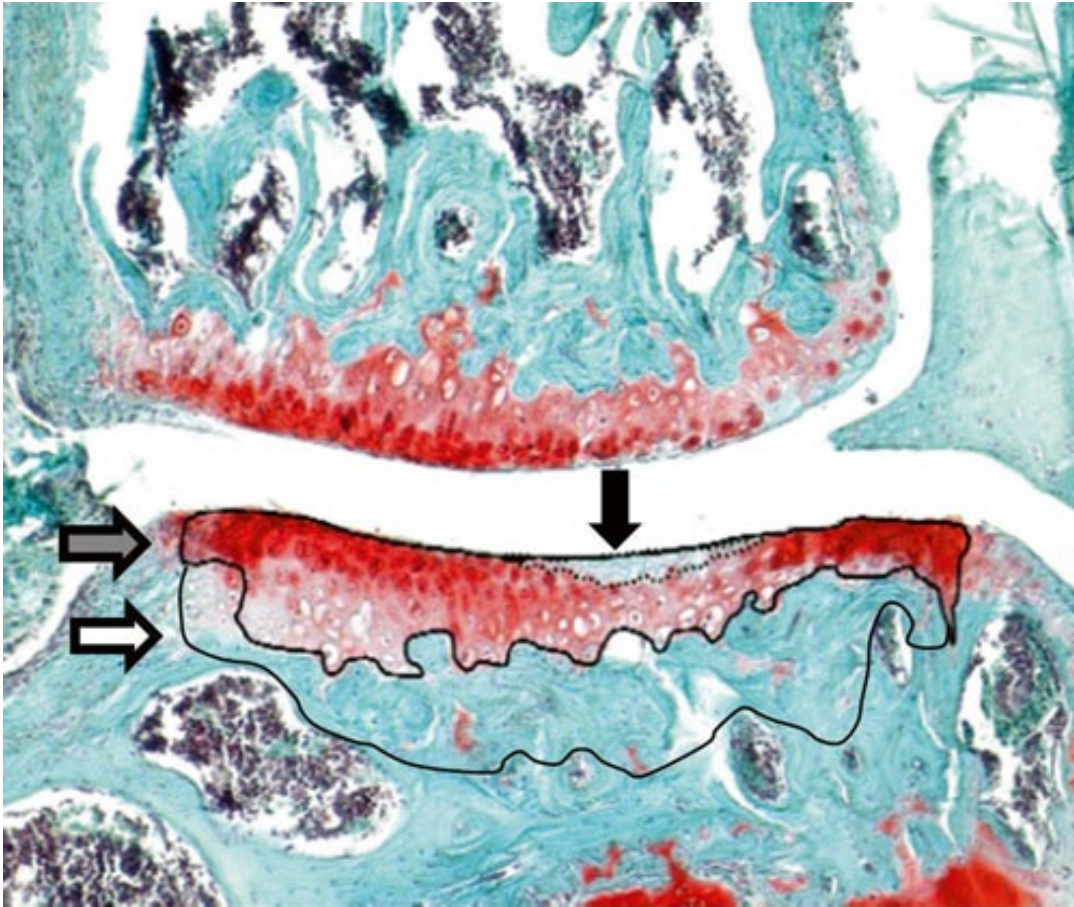
All samples were deparaffinized in two 6 and 8-min serial washes of xylene. After deparaffinizing, the sections were rehydrated using different concentrations of Ethanol from 100% to 70% then the slides were stained with hematoxylin for 3 min, and rinsed and placed in Scott's buffer for 2 min. After rinsing the slides into the tap water, slides were stained in 0.2% aqueous Fast green for 4 min and counterstaining with 0.5% Safranin O for 5 min. Lastly, the slides were dehydrated using ethanol serial dilution, then cleared in xylene, and mounted onto glass slides using Pre-mount. Each of the stained sections were evaluated under light microscope and photographed using a light microscope equipped with a CCD video camera.

Histomorphometric measurements were recorded by two blinded observers based on the semi-quantitative Modified Mankin scoring system recommended from the OARSI (155)(Table 3).

Grade	Osteoarthritic damage
0	Normal
0.5	Loss of Safranin-O without structural changes
1	Small fibrillation without loss of Cartilage
2	Vertical clefts down to the layer immediately below the superficial layer and some loss of surface lamina
3	Vertical clefts/erosion to the calcified cartilage extending to <25% of the articular surface
4	Vertical clefts/erosion to the calcified cartilage extending to <25-50% of the articular surface
om5	Vertical clefts/erosion to the calcified cartilage extending to <50-75% of the articular surface
6	Vertical clefts/erosion to the calcified cartilage extending to >75% of the articular surface

**Table 3:** Semi-quantitative Modified Mankin scoring system recommended

We evaluated all the specimens through all the weight bearing area of the joint with 50µm intervals. We scored each section according to the scoring system in the Table 2. We recorded the maximum number for each animal through the joint (figure 16).



**Figure 16:** Here is a representative image for morphometrical evaluation of osteoarthritis using a Safranin-O stained section. The histology image has taken from a right knee joint 4 weeks after DMM surgery. Black arrow shows area of acellular/unstained cartilage, grey arrow is the whole cartilage area and white arrow refers to subchondral bone plate (SBP). At  $\times 100$  magnification.

✓ *Immunohistochemistry staining:*

The samples were processed for paraffin embedding. For each knee joint, a series of sectioning each 6- $\mu$ m in thickness was taken. Approximately 120-150 sections represent the entire mouse knee joint from anterior to posterior side for the surgically induced OA mice. Every 20th section was collected for immunohistochemistry staining.

One slide from each mouse from all 3 groups has been selected for double immunohistostaining (Total of 6 or 7 per groups). The selection of the slide was based on the evaluation of safranin O/Fast Green stainings. We chose the slide right after or before the highest scored slide so in this case that one slide from each animal was representative of the worst condition of joint in each animal. Each slide contains up to 10 knee joint sections.

The sections were deparaffinized and quenched for endogenous peroxidase activity. The slides were incubated with primary polyclonal antibodies [rabbit polyclonal antibody against mouse MMP-13 (1:400 dilution, cat. AB8120; Chemicon, Temecula, CA)], at 4°C overnight. After washing with PBS, the slides were treated with secondary antibodies, goat anti-rabbit IgG Biotinylated at room temperature for 30 minutes. Color development was performed using a peroxidase substrate (Vector Nova-RED Substrate, cat. no. SK-4800; Vector Laboratories, Burlingame, CA) with avidin and biotinylated horseradish peroxidase (Vectastain ABC Kit, cat. no. PK-4000; Vector Laboratories).



Sections were counterstained with 0.2% Fast Green solution. Staining without primary antibody also were performed as negative controls.

✓ *Statistical analysis*

For experiments comparing two groups (e.g. relative mRNA expression), two-tailed unpaired student's t-test was applied. Results of all quantitative assays involving multiple time points (e.g. OARSI score of joint destruction) were analyzed using analysis of variance (ANOVA) followed by post-hoc tukey test.  $P < 0.05$  was considered to be significant difference.

## RESULTS

---

To evaluate the anti-inflammatory effects of HF and their possible therapeutic effects in OA, we initially evaluated the effects of HF on expression of MMP13, the important mediator of joint destruction, *in vitro*. To confirm the *in vitro* findings, we then evaluated the effect of administration of HF in an OA animal model *in vivo*.

*Inflammation induces overexpression of MMP-13 and HF inhibits inflammation-induced production of MMP-13.*

MMP-13 the central mediator in pathogenesis of OA and its overexpression is associated to joint destruction. The new paradigm of OA pathogenesis emphasizes on the role of inflammation in the progression of osteoarthritis. To evaluate the potential role of HF as a treatment that inhibit the progression of OA, we studied the effects of inflammation and addition of HF on MMP-13 mRNA expression. We used IL-1 $\beta$  and TNF- $\alpha$ , which are the main inflammatory cytokines in OA pathogenesis to produce the inflammatory environment, *in vitro*. We co-incubated chondrocytes with HF, IL-1 $\beta$ , or the combination of both, and compared the mRNA expression of MMP-13 to that of the untreated vehicle group. Inflammatory cytokine (addition of IL-1 $\beta$ ) significantly increased expression of MMP-13 (relative expression was  $13.77 \pm 1.3$ , p value= 0.006). When HF was also added

in addition to IL-1 $\beta$ , expression of MMP-13 was significantly reduced, close to the level of the untreated group (relative expression was  $1.73 \pm 0.9$ , p value= 0.01).

Compared to the vehicle group, adding HF alone did not significantly alter the expression of MMP-13 (relative expression was  $0.76 \pm 0.13$ , p value= 0.4). These results indicate that Inflammation induces overexpression of MMP-13 and HF inhibits inflammation-induced production of MMP-13. (Figure 17)

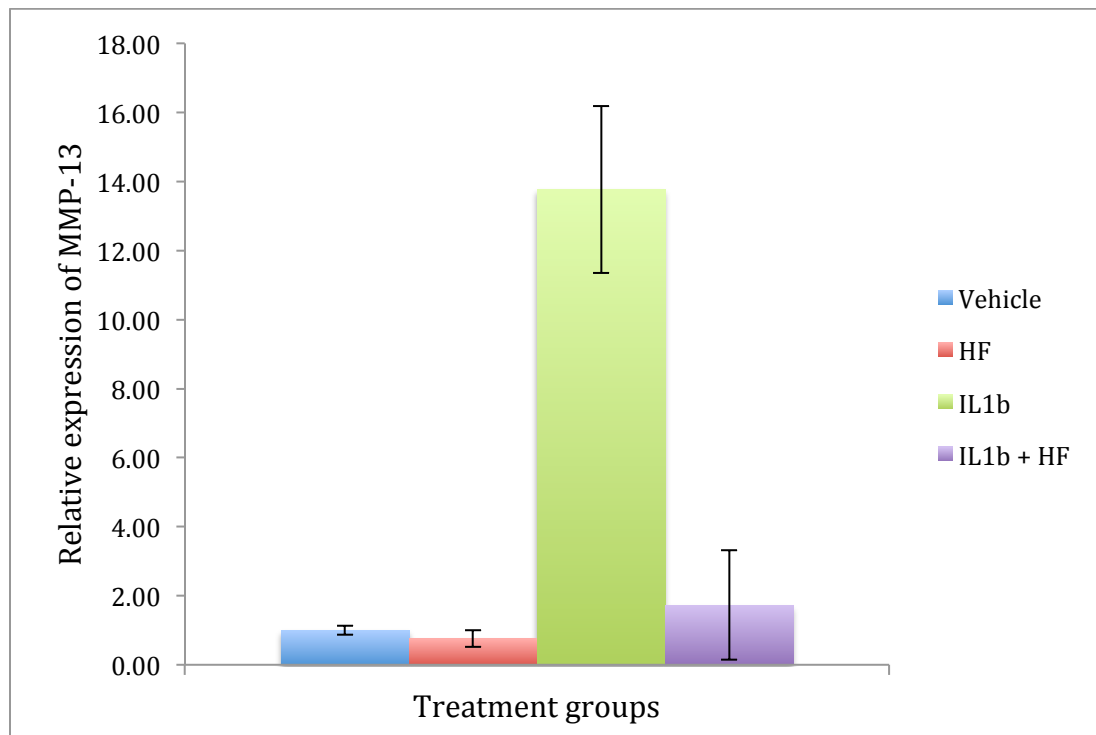


Figure 17: HF inhibits the expression of MMP-13 when it is co-incubated with the IL-1 $\beta$  in the CT28/I2 cells

To validate these findings, we also used TNF- $\alpha$  as another inflammatory marker and we observed similar results. Addition of TNF- $\alpha$  significantly increased the expression of MMP-13 while co-incubation of HF and TNF- $\alpha$  did not significantly alter MMP-13 compared to vehicle group, which indicates that addition of HF blocks TNF- $\alpha$  induced overexpression of MMP-13. (Figure 18)

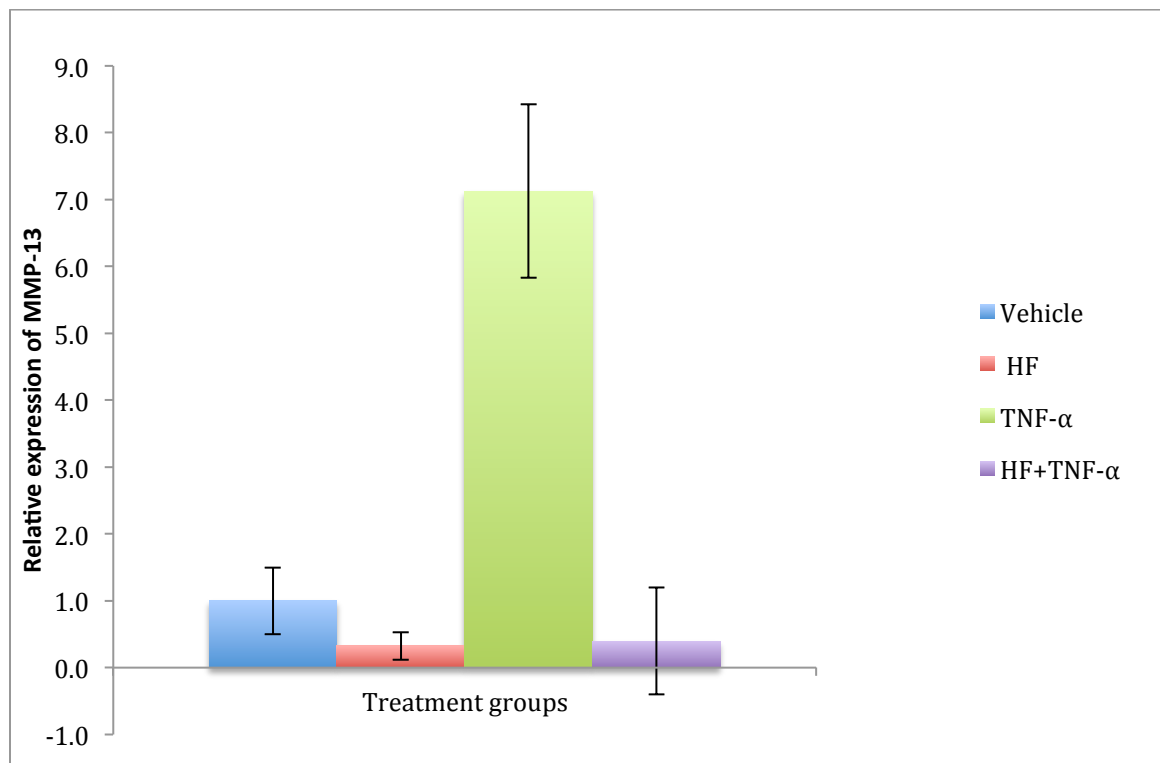


Figure 18: HF inhibits the expression of MMP-13 when it is co-incubated with the TNF- $\alpha$  in the CT28/I2 cells

Then to prove our findings, we used animal model of OA to see if HF will inhibit joint destruction and expression of MMP-13 and if timing of administration of HF would have any effect on the progression of OA.

*HF inhibits the joint destruction of OA in DMM-surgery osteoarthritic model.*

None of the animals had any health related issues after 12 weeks post DMM-surgery.

Neither surgery, nor the HF treatment caused any complication for the animals. Injection of HF in the mice osteoarthritis model significantly reduced Osteoarthritis progression according to OARSI scoring. The mean OARSI score for the DMM-surgery non-treated group was  $3.8 \pm 0.33$  vs. the scoring for the two treated groups  $1.16 \pm 0.38$  (in the group that had HF treatment 4 weeks post DMM surgery) and  $1.07 \pm 0.20$  (in the group that had HF treatment started right after the surgery) with the  $p$ -value  $< 0.05$ . Post hoc turkey test showed there was no difference between early vs. late administration of HF (Figure 19). Figure 20 illustrates representative Safranin O/Fast green staining of histologic sections of osteoarthritis induced by DMM surgery.

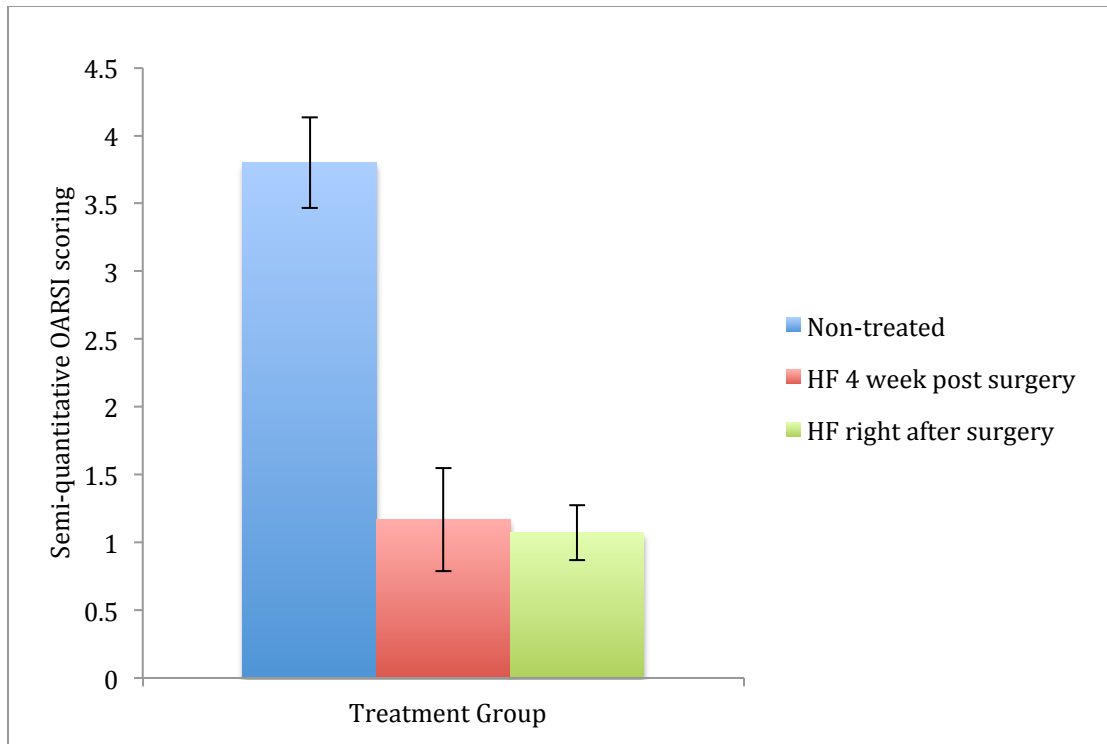


Figure 19: HF treatment reduced the progression of OA in DMM surgery osteoarthritis model

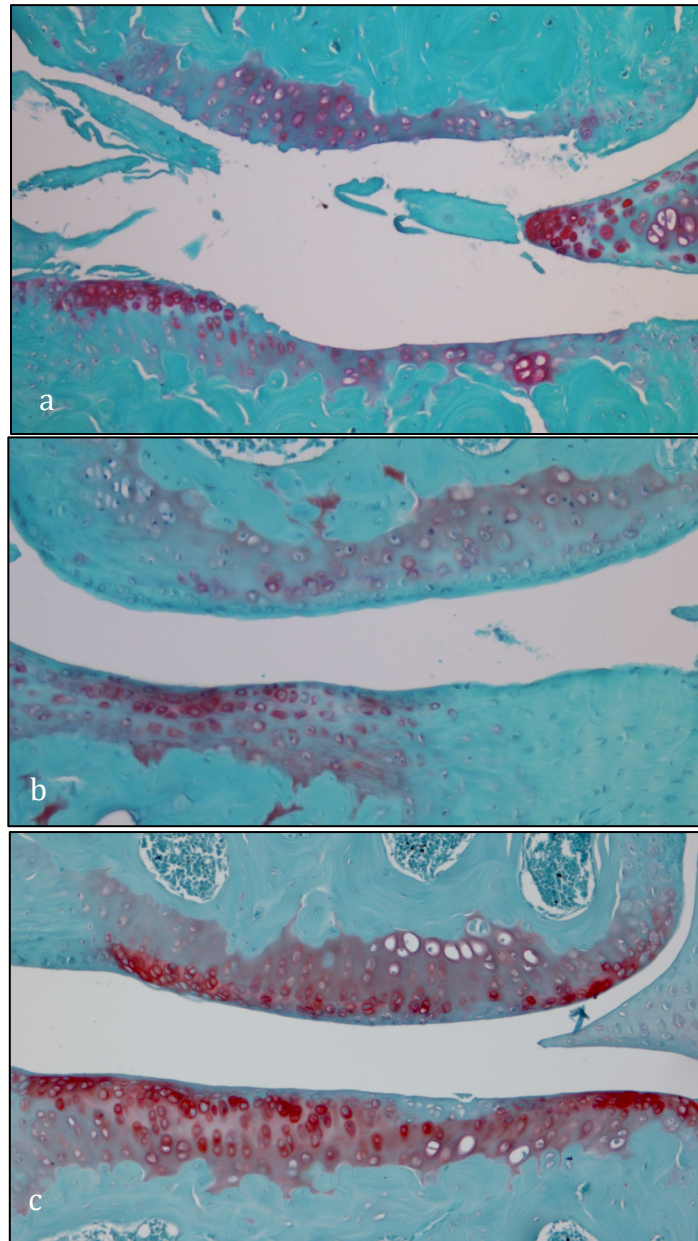
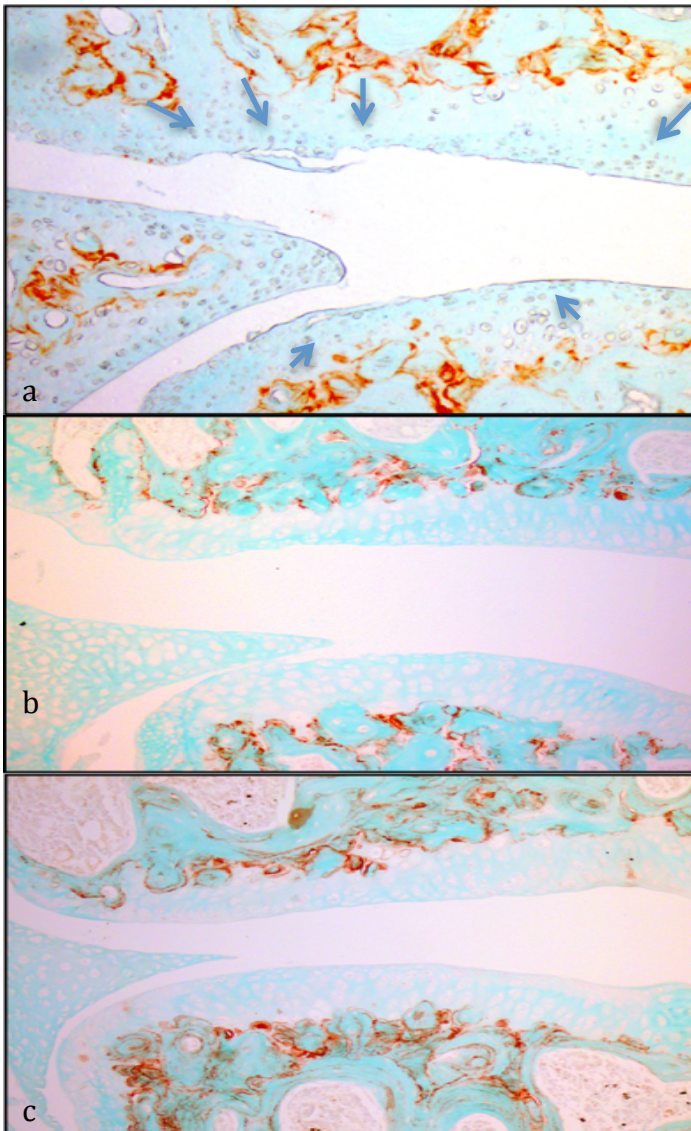


Figure 20: Safranin O/Fast green staining at 12 weeks after DMM surgery (10x magnification) (a) Control group (PBS injected, untreated animals) shows destruction of cartilage, wider erosion, irregular surface and demonstrates grade 5 OARSI semi-quantitative scoring. (b) Early treatment (HF injections 2 days post DMM surgery every other day for 12 weeks) demonstrates grade 0.5 OARSI semi-quantitative scoring (c) Late treatment (received Halofuginone injections 4 weeks post DMM surgery every other day for 8 weeks, and demonstrates grade 1 OARSI semi-quantitative scoring. In the treated animals (b and c) less cartilage destruction is observed compared to untreated animals (a).

*In vivo: HF reduces the expression of MMP-13 in DMM-surgery osteoarthritic model*

While MMP-13 was overexpressed in the control (DMM surgery without HF treatment) groups in IHC staining, expression of MMP13 was suppressed by injection of HF in both test groups and MMP13 was hardly detected in the both treated groups (figure 21).



**Figure 21:**

Immunohistochemistry staining for MMP-13, in histological sections of osteoarthritic knee induced by DMM surgery in mice model (a) Control group (PBS injected, untreated animals) prominent expression of MMP-13 (Brown spots pointed by blue arrows) (b) Early treatment (received HF injections 2 days post DMM surgery every other day for 12 weeks) and MMP-13 is hardly detected (c) Late Treatment (received Halofuginone injections 4 weeks post DMM surgery every other day for 8 weeks, and MMP-13 expression is rare. In (b) and (c) there is significantly less MMP-13 signal observed



## DISCUSSION

---

Current treatments for OA mainly focus on symptomatic management, such as medications to relieve the pain and maintaining quality of life and everyday activities of patients. The current therapeutic approach includes pharmacological therapy and surgery. The patient may start physical therapy (PT) or occupational therapy (OT) but when pain is severe and daily activities become difficult, surgery is recommended which is total joint replacement. As an example, knee OA patients wait, on average, 4.4 years from diagnosis to joint replacement (156). However, there is a tremendous need for non-surgical therapy and intervention to improve the quality of life of OA patients and currently, there are no proven therapies capable of preventing or slowing down the process of the disease. In this study, we investigated HF as a potential therapeutic drug for preventing the progression of OA. We hypothesized that HF inhibits OA associated joint destruction and inhibit the progression of OA by down regulation of MMP-13.

It has been proven that IL-1 $\beta$  and TNF- $\alpha$  up regulate the catabolic processes in OA and are important mediator cytokines in the development of the disease (68, 157-160). These inflammatory cytokines were shown to stimulate and significantly increase the expression of MMP-13 in chondrocytes (161-168). On the other hand, it is well established that the expression of MMP-13 is increased in OA and it plays a critical role in the destruction of cartilage and it is considered to be the main factor in the development and progression of

OA (169-171). Thus, hypothetically, suppressing IL-1 $\beta$  and TNF- $\alpha$  and subsequent down regulation of MMP-13 should inhibit the destructive processes induced by overexpression of MMP-13.

In line with the previous published studies, we showed in our *in vitro* studies that, expression of MMP-13 was significantly increased in the presence of the important inflammatory cytokines IL-1 $\beta$  and TNF- $\alpha$ . When HF was added to the chondrocytes that were co-incubated with IL-1 $\beta$  and TNF- $\alpha$ , the expression of MMP-13 was down regulated close to the baseline expression when there was no inflammatory cytokine added.

Suppressing effect of HF on MMP-13 was also confirmed in the *in vivo* model as well, where expression of MMP-13 was detected by IHC in control animals, while in those who were treated with HF, MMP-13 expression was suppressed.

To prove this hypothesis that administration of HF and subsequent suppression of MMP-13 will lead to prevention of joint destruction, we applied Safranin O/fast Green staining and OARSI scoring system which is the standard way to assess joint destruction. We observed that the destruction of joint was significantly decreased by administration of HF. In our animal model, in untreated animals there was successful induce of OA with joint destruction.

We also studied the timing of starting HF treatment on our preclinical model. We considered two time points for starting the treatment and administration of HF (early vs.

late) and observed that both of them effectively decreased joint destruction with no substantial difference. In other words, we showed that there is no difference if HF is administered during the acute phase of inflammation (right after DMM surgery), compared to delayed treatment (4 weeks after DMM surgery) when the acute inflammation has been resolved. Thus, according to these preclinical data, HF does not need to be immediately started after injury, to prevent injury induced osteoarthritis.

A therapeutic tool which can suppress inflammation induced MMP-13 can potentially be useful to inhibit joint destruction in OA. We showed that HF down regulates the production of MMP-13, thus, decreases the joint destruction associated with OA. In line with our results, there is one published study by Pines et al that demonstrates the role of HF in suppressing MMP-13 in pancreatic tumors where HF decreased MMP-13 levels significantly (172).

The inhibitory effect of HF on pro-inflammatory cytokines has been previously shown in various studies (128, 144, 145). Liang et al have demonstrated that HF significantly decreases the levels of TNF- $\alpha$  and IL-1 $\beta$  and it suppresses the secretion of inflammatory cytokines (173); these are the cytokines that play a critical role in pathogenesis of osteoarthritis and we have shown their impact on stimulation and upregulation of MMP-13.

Two different mechanisms of action have been described for HF. The first is inhibition of Th17 differentiation, which leads to inhibition of the inflammation by activation the AAR response by binding to prolyl-tRNA synthetase (127-129, 145). Th-17 cells produce pro-

inflammatory cytokines and have been shown to be active in OA as well (87-91). Therefore, inhibition of their differentiation can lead to diminished production of inflammatory cytokines and consequently, lower production of MMP-13. The second known mechanism of HF is inhibition of Smad3 phosphorylation and down regulation of the TGF- $\beta$  signaling pathway (124, 126). Morales et al has shown that TGF- $\beta$  is stored in cartilage in high amounts (174). Homandberg et al have demonstrated that following trauma and injury, TGF- $\beta$  is released from the ECM in the cartilage (175). There is also evidence that during OA, TGF- $\beta$  is increased in cartilage (176). Higher levels of TGF- $\beta$  have been reported in serum of OA patients and Kapetanakis et al claimed that there is a strong correlation between TGF- $\beta$  levels and severe pain and dysfunction according to a higher grade of Kellgren Lawrence and WOMAC scale (177). On the other hand, Xavier et al have reported that HF down regulates the Smad7 and TGF- $\beta$ , which leads to inhibiting the activation of Smad2 and Smad3 (178). All together, with HF down regulating the TGF- $\beta$  signaling, we would expect less cartilage damage in OA.

HF has been previously studied on different diseases like cancer (179-183), scleroderma (149) and demonstrated therapeutic effects as anti-malaria (184), anti-fibrotic (117, 126), inhibiting angiogenesis in the tumors (146) and anti-inflammatory effects (128, 144, 185). However, there was no published study on the effects of HF on OA to this date. This is the first study that evaluates the efficacy of HF in a preclinical OA model and these results introduce HF as an inhibitor for the progression of OA in DMM surgery in mice. HF is an FDA approved medication and it has been administered orally in a phase I

clinical trial for patients with solid tumors and has been proven to reach effective therapeutic plasma levels without any toxicity.

The result of this preclinical study shows that HF is a very potent inhibitor of MMP-13 expression and pathologic joint destruction in OA and p ave the ground for further clinical studies that are required to provide better insight into long-term outcomes relative to other treatment modalities and clarify whether inhibiting the pro-inflammatory cytokines and blocking the MMP-13 production by HF may replace current techniques as the gold standard.

## **CONCLUSIONS**

---

This is the first study that investigates Halofuginone (HF) for the prevention of progression of Osteoarthritis (OA). We demonstrate that HF inhibits inflammatory induced MMP-13 expression and diminishes joint destruction. There is no difference between administration of HF in acute early inflammatory phase verses late phase when acute inflammation has subsided. These preclinical findings provide supporting data for future clinical investigations for HF as a therapeutic target for osteoarthritis.

## REFERENCES

---

1. Hamerman D. The biology of osteoarthritis. *The New England journal of medicine*. 1989;320(20):1322-30.
2. Goldring MB, Goldring SR. Osteoarthritis. *J Cell Physiol*. 2007;213(3):626-34.
3. Lawrence RC, Felson DT, Helmick CG, Arnold LM, Choi H, Deyo RA, et al. Estimates of the prevalence of arthritis and other rheumatic conditions in the United States. Part II. Arthritis and rheumatism. 2008;58(1):26-35.
4. Felson DT. Clinical practice. Osteoarthritis of the knee. *N Engl J Med*. 2006;354(8):841-8.
5. Ethgen O, Kahler KH, Kong SX, Reginster JY, Wolfe F. The effect of health related quality of life on reported use of health care resources in patients with osteoarthritis and rheumatoid arthritis: a longitudinal analysis. *J Rheumatol*. 2002;29(6):1147-55.
6. Cevidanes LH, Walker D, Schilling J, Sugai J, Giannobile W, Paniagua B, et al. 3D osteoarthritic changes in TMJ condylar morphology correlates with specific systemic and local biomarkers of disease. *Osteoarthritis Cartilage*. 2014;22(10):1657-67.
7. Vincenti MP, Brinckerhoff CE. Transcriptional regulation of collagenase (MMP-1, MMP-13) genes in arthritis: integration of complex signaling pathways for the recruitment of gene-specific transcription factors. *Arthritis research*. 2002;4(3):157-64.
8. Wang M, Shen J, Jin H, Im HJ, Sandy J, Chen D. Recent progress in understanding molecular mechanisms of cartilage degeneration during osteoarthritis. *Annals of the New York Academy of Sciences*. 2011;1240:61-9.
9. Goldring SR. The role of bone in osteoarthritis pathogenesis. *Rheumatic diseases clinics of North America*. 2008;34(3):561-71.
10. van der Kraan PM, Blaney Davidson EN, Blom A, van den Berg WB. TGF-beta signaling in chondrocyte terminal differentiation and osteoarthritis: modulation and integration of signaling pathways through receptor-Smads. *Osteoarthritis Cartilage*. 2009;17(12):1539-45.
11. Heinegard D, Saxne T. The role of the cartilage matrix in osteoarthritis. *Nature reviews Rheumatology*. 2011;7(1):50-6.
12. Goldring MB, Otero M. Inflammation in osteoarthritis. *Current opinion in rheumatology*. 2011;23(5):471-8.
13. Goldring MB. Articular cartilage degradation in osteoarthritis. *HSS journal : the musculoskeletal journal of Hospital for Special Surgery*. 2012;8(1):7-9.

14. Goldring MB, Otero M, Plumb DA, Dragomir C, Favero M, El Hachem K, et al. Roles of inflammatory and anabolic cytokines in cartilage metabolism: signals and multiple effectors converge upon MMP-13 regulation in osteoarthritis. *European cells & materials*. 2011;21:202-20.
15. Brew CJ, Clegg PD, Boot-Handford RP, Andrew JG, Hardingham T. Gene expression in human chondrocytes in late osteoarthritis is changed in both fibrillated and intact cartilage without evidence of generalised chondrocyte hypertrophy. *Annals of the rheumatic diseases*. 2010;69(1):234-40.
16. Scanzello CR, Goldring SR. The role of synovitis in osteoarthritis pathogenesis. *Bone*. 2012;51(2):249-57.
17. Blaney Davidson EN, van der Kraan PM, van den Berg WB. TGF-beta and osteoarthritis. *Osteoarthritis Cartilage*. 2007;15(6):597-604.
18. Song B, Estrada KD, Lyons KM. Smad signaling in skeletal development and regeneration. *Cytokine Growth Factor Rev*. 2009;20(5-6):379-88.
19. van der Kraan PM, Blaney Davidson EN, van den Berg WB. A role for age-related changes in TGFbeta signaling in aberrant chondrocyte differentiation and osteoarthritis. *Arthritis Res Ther*. 2010;12(1):201.
20. Malemud CJ. Anticytokine therapy for osteoarthritis: evidence to date. *Drugs Aging*. 2010;27(2):95-115.
21. Goldring MB, Tsuchimochi K, Ijiri K. The control of chondrogenesis. *J Cell Biochem*. 2006;97(1):33-44.
22. Onyekwelu I, Goldring MB, Hidaka C. Chondrogenesis, joint formation, and articular cartilage regeneration. *Journal of cellular biochemistry*. 2009;107(3):383-92.
23. Quintana L, zur Nieden NI, Semino CE. Morphogenetic and regulatory mechanisms during developmental chondrogenesis: new paradigms for cartilage tissue engineering. *Tissue Eng Part B Rev*. 2009;15(1):29-41.
24. Valcourt U, Gouttenoire J, Moustakas A, Herbage D, Mallein-Gerin F. Functions of transforming growth factor-beta family type I receptors and Smad proteins in the hypertrophic maturation and osteoblastic differentiation of chondrocytes. *J Biol Chem*. 2002;277(37):33545-58.
25. Blaney Davidson EN, Remst DF, Vitters EL, van Beuningen HM, Blom AB, Goumans MJ, et al. Increase in ALK1/ALK5 ratio as a cause for elevated MMP-13 expression in osteoarthritis in humans and mice. *J Immunol*. 2009;182(12):7937-45.
26. Blaney Davidson EN, Vitters EL, van der Kraan PM, van den Berg WB. Expression of transforming growth factor-beta (TGFbeta) and the TGFbeta signalling molecule SMAD-2P in spontaneous and instability-induced osteoarthritis: role in cartilage degradation, chondrogenesis and osteophyte formation. *Ann Rheum Dis*. 2006;65(11):1414-21.
27. Blaney Davidson EN, Scharstuhl A, Vitters EL, van der Kraan PM, van den Berg WB. Reduced transforming growth factor-beta signaling in cartilage of old mice: role in impaired repair capacity. *Arthritis Res Ther*. 2005;7(6):R1338-47.



28. Millward-Sadler SJ, Salter DM. Integrin-dependent signal cascades in chondrocyte mechanotransduction. *Annals of biomedical engineering*. 2004;32(3):435-46.
29. Kamekura S, Kawasaki Y, Hoshi K, Shimoaka T, Chikuda H, Maruyama Z, et al. Contribution of runt-related transcription factor 2 to the pathogenesis of osteoarthritis in mice after induction of knee joint instability. *Arthritis and rheumatism*. 2006;54(8):2462-70.
30. Cecil DL, Appleton CT, Polewski MD, Mort JS, Schmidt AM, Bendele A, et al. The pattern recognition receptor CD36 is a chondrocyte hypertrophy marker associated with suppression of catabolic responses and promotion of repair responses to inflammatory stimuli. *Journal of immunology*. 2009;182(8):5024-31.
31. Husa M, Liu-Bryan R, Terkeltaub R. Shifting HIFs in osteoarthritis. *Nature medicine*. 2010;16(6):641-4.
32. Saito T, Fukai A, Mabuchi A, Ikeda T, Yano F, Ohba S, et al. Transcriptional regulation of endochondral ossification by HIF-2alpha during skeletal growth and osteoarthritis development. *Nature medicine*. 2010;16(6):678-86.
33. Yang S, Kim J, Ryu JH, Oh H, Chun CH, Kim BJ, et al. Hypoxia-inducible factor-2alpha is a catabolic regulator of osteoarthritic cartilage destruction. *Nature medicine*. 2010;16(6):687-93.
34. Ding L, Heying E, Nicholson N, Stroud NJ, Homandberg GA, Buckwalter JA, et al. Mechanical impact induces cartilage degradation via mitogen activated protein kinases. *Osteoarthritis and cartilage / OARS, Osteoarthritis Research Society*. 2010;18(11):1509-17.
35. Goodwin W, McCabe D, Sauter E, Reese E, Walter M, Buckwalter JA, et al. Rotenone prevents impact-induced chondrocyte death. *Journal of orthopaedic research : official publication of the Orthopaedic Research Society*. 2010;28(8):1057-63.
36. Fitzgerald GK, Piva SR, Irrgang JJ. Reports of joint instability in knee osteoarthritis: its prevalence and relationship to physical function. *Arthritis and rheumatism*. 2004;51(6):941-6.
37. Wang M, Sampson ER, Jin H, Li J, Ke QH, Im HJ, et al. MMP13 is a critical target gene during the progression of osteoarthritis. *Arthritis research & therapy*. 2013;15(1):R5.
38. Xu L, Servais J, Polur I, Kim D, Lee PL, Chung K, et al. Attenuation of osteoarthritis progression by reduction of discoidin domain receptor 2 in mice. *Arthritis and rheumatism*. 2010;62(9):2736-44.
39. Klatt AR, Zech D, Kuhn G, Paul-Klausch B, Klinger G, Renno JH, et al. Discoidin domain receptor 2 mediates the collagen II-dependent release of interleukin-6 in primary human chondrocytes. *J Pathol*. 2009;218(2):241-7.
40. Klatt AR, Paul-Klausch B, Klinger G, Kuhn G, Renno JH, Banerjee M, et al. A critical role for collagen II in cartilage matrix degradation: collagen II induces pro-

inflammatory cytokines and MMPs in primary human chondrocytes. *J Orthop Res.* 2009;27(1):65-70.

41. Polur I, Lee PL, Servais JM, Xu L, Li Y. Role of HTRA1, a serine protease, in the progression of articular cartilage degeneration. *Histology and histopathology.* 2010;25(5):599-608.

42. Vlad SC, Neogi T, Aliabadi P, Fontes JD, Felson DT. No association between markers of inflammation and osteoarthritis of the hands and knees. *The Journal of rheumatology.* 2011;38(8):1665-70.

43. Gobeze R, Kho A, Krastins B, Sarracino DA, Thornhill TS, Chase M, et al. High abundance synovial fluid proteome: distinct profiles in health and osteoarthritis. *Arthritis research & therapy.* 2007;9(2):R36.

44. Ayral X. [Efficacy and role of topical treatment of gonarthrosis]. *Presse medicale.* 1999;28(22):1195-200.

45. Krasnokutsky S, Attur M, Palmer G, Samuels J, Abramson SB. Current concepts in the pathogenesis of osteoarthritis. *Osteoarthritis and cartilage / OARS, Osteoarthritis Research Society.* 2008;16 Suppl 3:S1-3.

46. Ostergaard M, Stoltenberg M, Lovgreen-Nielsen P, Volck B, Jensen CH, Lorenzen I. Magnetic resonance imaging-determined synovial membrane and joint effusion volumes in rheumatoid arthritis and osteoarthritis: comparison with the macroscopic and microscopic appearance of the synovium. *Arthritis and rheumatism.* 1997;40(10):1856-67.

47. Fernandez-Madrid F, Karvonen RL, Teitge RA, Miller PR, An T, Negendank WG. Synovial thickening detected by MR imaging in osteoarthritis of the knee confirmed by biopsy as synovitis. *Magnetic resonance imaging.* 1995;13(2):177-83.

48. Ayral X, Ravaud P, Bonvarlet JP, Simonnet J, Lecurieux R, Nguyen M, et al. Arthroscopic evaluation of post-traumatic patellofemoral chondropathy. *The Journal of rheumatology.* 1999;26(5):1140-7.

49. Loeuille D, Chary-Valckenaere I, Champigneulle J, Rat AC, Toussaint F, Pinzano-Watrin A, et al. Macroscopic and microscopic features of synovial membrane inflammation in the osteoarthritic knee: correlating magnetic resonance imaging findings with disease severity. *Arthritis and rheumatism.* 2005;52(11):3492-501.

50. D'Agostino MA, Conaghan P, Le Bars M, Baron G, Grassi W, Martin-Mola E, et al. EULAR report on the use of ultrasonography in painful knee osteoarthritis. Part 1: prevalence of inflammation in osteoarthritis. *Annals of the rheumatic diseases.* 2005;64(12):1703-9.

51. Ayral X, Pickering EH, Woodworth TG, Mackillop N, Dougados M. Synovitis: a potential predictive factor of structural progression of medial tibiofemoral knee osteoarthritis -- results of a 1 year longitudinal arthroscopic study in 422 patients. *Osteoarthritis and cartilage / OARS, Osteoarthritis Research Society.* 2005;13(5):361-7.

52. Keen HI, Wakefield RJ, Grainger AJ, Hensor EM, Emery P, Conaghan PG. Can ultrasonography improve on radiographic assessment in osteoarthritis of the hands? A comparison between radiographic and ultrasonographic detected pathology. *Annals of the rheumatic diseases*. 2008;67(8):1116-20.
53. Myers SL, Brandt KD, Ehlich JW, Braunstein EM, Shelbourne KD, Heck DA, et al. Synovial inflammation in patients with early osteoarthritis of the knee. *The Journal of rheumatology*. 1990;17(12):1662-9.
54. Alsalameh S, Mollenhauer J, Hain N, Stock KP, Kalden JR, Burmester GR. Cellular immune response toward human articular chondrocytes. T cell reactivities against chondrocyte and fibroblast membranes in destructive joint diseases. *Arthritis and rheumatism*. 1990;33(10):1477-86.
55. Nakamura H, Yoshino S, Kato T, Tsuruha J, Nishioka K. T-cell mediated inflammatory pathway in osteoarthritis. *Osteoarthritis and cartilage / OARS, Osteoarthritis Research Society*. 1999;7(4):401-2.
56. Shibakawa A, Aoki H, Masuko-Hongo K, Kato T, Tanaka M, Nishioka K, et al. Presence of pannus-like tissue on osteoarthritic cartilage and its histological character. *Osteoarthritis and cartilage / OARS, Osteoarthritis Research Society*. 2003;11(2):133-40.
57. Walsh DA, Bonnet CS, Turner EL, Wilson D, Situ M, McWilliams DF. Angiogenesis in the synovium and at the osteochondral junction in osteoarthritis. *Osteoarthritis and cartilage / OARS, Osteoarthritis Research Society*. 2007;15(7):743-51.
58. Sellam J, Berenbaum F. The role of synovitis in pathophysiology and clinical symptoms of osteoarthritis. *Nature reviews Rheumatology*. 2010;6(11):625-35.
59. Maldonado M, Nam J. The role of changes in extracellular matrix of cartilage in the presence of inflammation on the pathology of osteoarthritis. *BioMed research international*. 2013;2013:284873.
60. Smith MD, Triantafyllou S, Parker A, Youssef PP, Coleman M. Synovial membrane inflammation and cytokine production in patients with early osteoarthritis. *The Journal of rheumatology*. 1997;24(2):365-71.
61. Furuzawa-Carballeda J, Alcocer-Varela J. Interleukin-8, interleukin-10, intercellular adhesion molecule-1 and vascular cell adhesion molecule-1 expression levels are higher in synovial tissue from patients with rheumatoid arthritis than in osteoarthritis. *Scandinavian journal of immunology*. 1999;50(2):215-22.
62. Niissalo S, Hukkanen M, Imai S, Tornwall J, Konttinen YT. Neuropeptides in experimental and degenerative arthritis. *Annals of the New York Academy of Sciences*. 2002;966:384-99.
63. Farahat MN, Yanni G, Poston R, Panayi GS. Cytokine expression in synovial membranes of patients with rheumatoid arthritis and osteoarthritis. *Annals of the rheumatic diseases*. 1993;52(12):870-5.
64. Yuan GH, Tanaka M, Masuko-Hongo K, Shibakawa A, Kato T, Nishioka K, et al. Characterization of cells from pannus-like tissue over articular cartilage of advanced

- osteoarthritis. *Osteoarthritis and cartilage / OARS, Osteoarthritis Research Society*. 2004;12(1):38-45.
65. Benito MJ, Veale DJ, FitzGerald O, van den Berg WB, Bresnihan B. Synovial tissue inflammation in early and late osteoarthritis. *Annals of the rheumatic diseases*. 2005;64(9):1263-7.
66. Presle N, Pottie P, Dumond H, Guillaume C, Lopicque F, Pallu S, et al. Differential distribution of adipokines between serum and synovial fluid in patients with osteoarthritis. Contribution of joint tissues to their articular production. *Osteoarthritis and cartilage / OARS, Osteoarthritis Research Society*. 2006;14(7):690-5.
67. Brentano F, Schorr O, Ospelt C, Stanczyk J, Gay RE, Gay S, et al. Pre-B cell colony-enhancing factor/visfatin, a new marker of inflammation in rheumatoid arthritis with proinflammatory and matrix-degrading activities. *Arthritis and rheumatism*. 2007;56(9):2829-39.
68. Scanzello CR, Umoh E, Pessler F, Diaz-Torne C, Miles T, DiCarlo E, et al. Local cytokine profiles in knee osteoarthritis: elevated synovial fluid interleukin-15 differentiates early from end-stage disease. *Osteoarthritis Cartilage*. 2009;17(8):1040-8.
69. Raychaudhuri SP, Raychaudhuri SK. The regulatory role of nerve growth factor and its receptor system in fibroblast-like synovial cells. *Scandinavian journal of rheumatology*. 2009;38(3):207-15.
70. Conrozier T, Carlier MC, Mathieu P, Colson F, Debard AL, Richard S, et al. Serum levels of YKL-40 and C reactive protein in patients with hip osteoarthritis and healthy subjects: a cross sectional study. *Annals of the rheumatic diseases*. 2000;59(10):828-31.
71. Masuhara K, Nakai T, Yamaguchi K, Yamasaki S, Sasaguri Y. Significant increases in serum and plasma concentrations of matrix metalloproteinases 3 and 9 in patients with rapidly destructive osteoarthritis of the hip. *Arthritis and rheumatism*. 2002;46(10):2625-31.
72. Pearle AD, Scanzello CR, George S, Mandl LA, DiCarlo EF, Peterson M, et al. Elevated high-sensitivity C-reactive protein levels are associated with local inflammatory findings in patients with osteoarthritis. *Osteoarthritis and cartilage / OARS, Osteoarthritis Research Society*. 2007;15(5):516-23.
73. Gierman LM, van der Ham F, Koudijs A, Wielinga PY, Kleemann R, Kooistra T, et al. Metabolic stress-induced inflammation plays a major role in the development of osteoarthritis in mice. *Arthritis Rheum*. 2012;64(4):1172-81.
74. Houard X, Goldring MB, Berenbaum F. Homeostatic mechanisms in articular cartilage and role of inflammation in osteoarthritis. *Current rheumatology reports*. 2013;15(11):375.
75. Henrotin Y, Lambert C, Richette P. Importance of synovitis in osteoarthritis: evidence for the use of glycosaminoglycans against synovial inflammation. *Semin Arthritis Rheum*. 2014;43(5):579-87.

76. Hermann J, Lipp RW, Dunzinger A, Spreizer C, Schaffler G, Kvaternik H, et al. Anti-TNF scintigraphy to assess TNF-alpha-associated joint inflammation in rheumatoid arthritis and osteoarthritis. *Clin Exp Rheumatol*. 2014;32(4):614.
77. Siebuhr AS, Petersen KK, Arendt-Nielsen L, Egsgaard LL, Eskehave T, Christiansen C, et al. Identification and characterisation of osteoarthritis patients with inflammation derived tissue turnover. *Osteoarthritis Cartilage*. 2014;22(1):44-50.
78. Gross JB, Guillaume C, Gegout-Pottie P, Mainard D, Presle N. Synovial fluid levels of adipokines in osteoarthritis: Association with local factors of inflammation and cartilage maintenance. *Biomed Mater Eng*. 2014;24(1 Suppl):17-25.
79. Goldring MB, Marcu KB. Cartilage homeostasis in health and rheumatic diseases. *Arthritis research & therapy*. 2009;11(3):224.
80. Olivotto E, Borzi RM, Vitellozzi R, Pagani S, Facchini A, Battistelli M, et al. Differential requirements for IKKalpha and IKKbeta in the differentiation of primary human osteoarthritic chondrocytes. *Arthritis and rheumatism*. 2008;58(1):227-39.
81. Tchetina EV, Squires G, Poole AR. Increased type II collagen degradation and very early focal cartilage degeneration is associated with upregulation of chondrocyte differentiation related genes in early human articular cartilage lesions. *The Journal of rheumatology*. 2005;32(5):876-86.
82. Torzilli PA, Bhargava M, Park S, Chen CT. Mechanical load inhibits IL-1 induced matrix degradation in articular cartilage. *Osteoarthritis and cartilage / OARS, Osteoarthritis Research Society*. 2010;18(1):97-105.
83. Korn T, Bettelli E, Oukka M, Kuchroo VK. IL-17 and Th17 Cells. *Annual review of immunology*. 2009;27:485-517.
84. Dong C. TH17 cells in development: an updated view of their molecular identity and genetic programming. *Nature reviews Immunology*. 2008;8(5):337-48.
85. McGeachy MJ, Cua DJ. Th17 cell differentiation: the long and winding road. *Immunity*. 2008;28(4):445-53.
86. Acosta-Rodriguez EV, Napolitani G, Lanzavecchia A, Sallusto F. Interleukins 1beta and 6 but not transforming growth factor-beta are essential for the differentiation of interleukin 17-producing human T helper cells. *Nat Immunol*. 2007;8(9):942-9.
87. Umemura M, Yahagi A, Hamada S, Begum MD, Watanabe H, Kawakami K, et al. IL-17-mediated regulation of innate and acquired immune response against pulmonary *Mycobacterium bovis* bacille Calmette-Guerin infection. *J Immunol*. 2007;178(6):3786-96.
88. Torrado E, Cooper AM. IL-17 and Th17 cells in tuberculosis. *Cytokine Growth Factor Rev*. 2010;21(6):455-62.
89. Gonzalez-Lombana C, Gimblet C, Bacellar O, Oliveira WW, Passos S, Carvalho LP, et al. IL-17 mediates immunopathology in the absence of IL-10 following *Leishmania major* infection. *PLoS Pathog*. 2013;9(3):e1003243.

90. Curtis MM, Way SS. Interleukin-17 in host defence against bacterial, mycobacterial and fungal pathogens. *Immunology*. 2009;126(2):177-85.
91. Lurati A, RK, Gatti A., Brando B. Different distribution and activation degree of th17 cells in peripheral blood in patients with osteoarthritis, rheumatoid arthritis and healthy donors: preliminary results of the magenta clicao (clinical cell analysis in osteoarthritis) study. *Osteoarthritis Cartilage*. 2014;22:S295-S6.
92. Roos EM. Joint injury causes knee osteoarthritis in young adults. *Current opinion in rheumatology*. 2005;17(2):195-200.
93. Guilak F, Fermor B, Keefe FJ, Kraus VB, Olson SA, Pisetsky DS, et al. The role of biomechanics and inflammation in cartilage injury and repair. *Clinical orthopaedics and related research*. 2004(423):17-26.
94. Hunter DJ. Pharmacologic therapy for osteoarthritis--the era of disease modification. *Nature reviews Rheumatology*. 2011;7(1):13-22.
95. Baker K, Grainger A, Niu J, Clancy M, Guermazi A, Crema M, et al. Relation of synovitis to knee pain using contrast-enhanced MRIs. *Annals of the rheumatic diseases*. 2010;69(10):1779-83.
96. Attur M, Samuels J, Krasnokutsky S, Abramson SB. Targeting the synovial tissue for treating osteoarthritis (OA): where is the evidence? Best practice & research *Clinical rheumatology*. 2010;24(1):71-9.
97. Yokota H, Leong DJ, Sun HB. Mechanical loading: bone remodeling and cartilage maintenance. *Current osteoporosis reports*. 2011;9(4):237-42.
98. Quinn JH, Bazan NG. Identification of prostaglandin E2 and leukotriene B4 in the synovial fluid of painful, dysfunctional temporomandibular joints. *Journal of oral and maxillofacial surgery : official journal of the American Association of Oral and Maxillofacial Surgeons*. 1990;48(9):968-71.
99. Holmlund A, Ekblom A, Hansson P, Lind J, Lundeberg T, Theodorsson E. Concentrations of neuropeptides substance P, neurokinin A, calcitonin gene-related peptide, neuropeptide Y and vasoactive intestinal polypeptide in synovial fluid of the human temporomandibular joint. A correlation with symptoms, signs and arthroscopic findings. *International journal of oral and maxillofacial surgery*. 1991;20(4):228-31.
100. Vos LM, Kuijer R, Huddleston Slater JJ, Bulstra SK, Stegenga B. Inflammation is more distinct in temporomandibular joint osteoarthritis compared to the knee joint. *Journal of oral and maxillofacial surgery : official journal of the American Association of Oral and Maxillofacial Surgeons*. 2014;72(1):35-40.
101. Barros Vde M, Seraidarian PI, Cortes MI, de Paula LV. The impact of orofacial pain on the quality of life of patients with temporomandibular disorder. *Journal of orofacial pain*. 2009;23(1):28-37.
102. John MT, Reissmann DR, Schierz O, Wassell RW. Oral health-related quality of life in patients with temporomandibular disorders. *Journal of orofacial pain*. 2007;21(1):46-54.

103. Zarb GA, Carlsson GE. Temporomandibular disorders: osteoarthritis. *Journal of orofacial pain.* 1999;13(4):295-306.
104. Shahidi S, Vojdani M, Paknahad M. Correlation between articular eminence steepness measured with cone-beam computed tomography and clinical dysfunction index in patients with temporomandibular joint dysfunction. *Oral surgery, oral medicine, oral pathology and oral radiology.* 2013;116(1):91-7.
105. Su N, Liu Y, Yang X, Luo Z, Shi Z. Correlation between bony changes measured with cone beam computed tomography and clinical dysfunction index in patients with temporomandibular joint osteoarthritis. *Journal of cranio-maxillo-facial surgery : official publication of the European Association for Cranio-Maxillo-Facial Surgery.* 2014;42(7):1402-7.
106. Poole R, Blake S, Buschmann M, Goldring S, Laverty S, Lockwood S, et al. Recommendations for the use of preclinical models in the study and treatment of osteoarthritis. *Osteoarthritis and cartilage / OARS, Osteoarthritis Research Society.* 2010;18 Suppl 3:S10-6.
107. Blom AB, van Lent PL, Libregts S, Holthuysen AE, van der Kraan PM, van Rooijen N, et al. Crucial role of macrophages in matrix metalloproteinase-mediated cartilage destruction during experimental osteoarthritis: involvement of matrix metalloproteinase 3. *Arthritis Rheum.* 2007;56(1):147-57.
108. van der Kraan PM, Vitters EL, van de Putte LB, van den Berg WB. Development of osteoarthritic lesions in mice by "metabolic" and "mechanical" alterations in the knee joints. *Am J Pathol.* 1989;135(6):1001-14.
109. Visco DM, Hill MA, Widmer WR, Johnstone B, Myers SL. Experimental osteoarthritis in dogs: a comparison of the Pond-Nuki and medial arthrotomy methods. *Osteoarthritis Cartilage.* 1996;4(1):9-22.
110. Clements KM, Price JS, Chambers MG, Visco DM, Poole AR, Mason RM. Gene deletion of either interleukin-1beta, interleukin-1beta-converting enzyme, inducible nitric oxide synthase, or stromelysin 1 accelerates the development of knee osteoarthritis in mice after surgical transection of the medial collateral ligament and partial medial meniscectomy. *Arthritis Rheum.* 2003;48(12):3452-63.
111. Kamekura S, Hoshi K, Shimoaka T, Chung U, Chikuda H, Yamada T, et al. Osteoarthritis development in novel experimental mouse models induced by knee joint instability. *Osteoarthritis Cartilage.* 2005;13(7):632-41.
112. Poole AR. An introduction to the pathophysiology of osteoarthritis. *Front Biosci.* 1999;4:D662-70.
113. Santori N, Villar RN. Arthroscopic findings in the initial stages of hip osteoarthritis. *Orthopedics.* 1999;22(4):405-9.
114. Glasson SS, Blanchet TJ, Morris EA. The surgical destabilization of the medial meniscus (DMM) model of osteoarthritis in the 129/SvEv mouse. *Osteoarthritis Cartilage.* 2007;15(9):1061-9.

115. Glasson SS, Askew R, Sheppard B, Carito B, Blanchet T, Ma HL, et al. Deletion of active ADAMTS5 prevents cartilage degradation in a murine model of osteoarthritis. *Nature*. 2005;434(7033):644-8.
116. Glasson SS, Askew R, Sheppard B, Carito BA, Blanchet T, Ma HL, et al. Characterization of and osteoarthritis susceptibility in ADAMTS-4-knockout mice. *Arthritis Rheum*. 2004;50(8):2547-58.
117. Pines M, Nagler A. Halofuginone: a novel antifibrotic therapy. *Gen Pharmacol*. 1998;30(4):445-50.
118. Jang CS, Fu FY, et al. Pharmacology of ch'ang shan (*Dichroa febrifuga*) a Chinese antimalarial herb. *Nature*. 1948;161(4089):400.
119. Zhang DF, Sun BB, Yue YY, Yu HJ, Zhang HL, Zhou QJ, et al. Anticoccidial effect of halofuginone hydrobromide against *Eimeria tenella* with associated histology. *Parasitology research*. 2012;111(2):695-701.
120. Pinion JL, Bilgili SF, Eckman MK, Hess JB. The effects of halofuginone and salinomycin, alone and in combination, on live performance and skin characteristics of broilers. *Poultry science*. 1995;74(2):391-7.
121. Dauschies A, Gasslein U, Rommel M. Comparative efficacy of anticoccidials under the conditions of commercial broiler production and in battery trials. *Veterinary parasitology*. 1998;76(3):163-71.
122. Peeters JE, Villacorta I, Naciri M, Vanopdenbosch E. Specific serum and local antibody responses against *Cryptosporidium parvum* during medication of calves with halofuginone lactate. *Infection and immunity*. 1993;61(10):4440-5.
123. Park MK, Park JS, Park EM, Lim MA, Kim SM, Lee DG, et al. Halofuginone ameliorates autoimmune arthritis in mice by regulating the balance between Th17 and Treg cells and inhibiting osteoclastogenesis. *Arthritis Rheumatol*. 2014;66(5):1195-207.
124. Pines M. Halofuginone for fibrosis, regeneration and cancer in the gastrointestinal tract. *World J Gastroenterol*. 2014;20(40):14778-86.
125. Jin ML, Park SY, Kim YH, Park G, Lee SJ. Halofuginone induces the apoptosis of breast cancer cells and inhibits migration via downregulation of matrix metalloproteinase-9. *Int J Oncol*. 2014;44(1):309-18.
126. Pines M. Targeting TGFbeta signaling to inhibit fibroblast activation as a therapy for fibrosis and cancer: effect of halofuginone. *Expert Opin Drug Discov*. 2008;3(1):11-20.
127. Keller TL, Zocco D, Sundrud MS, Hendrick M, Edenius M, Yum J, et al. Halofuginone and other febrifugine derivatives inhibit prolyl-tRNA synthetase. *Nat Chem Biol*. 2012;8(3):311-7.
128. Sundrud MS, Koralov SB, Feuerer M, Calado DP, Kozhaya AE, Rhule-Smith A, et al. Halofuginone inhibits TH17 cell differentiation by activating the amino acid starvation response. *Science*. 2009;324(5932):1334-8.
129. Son J, Lee EH, Park M, Kim JH, Kim J, Kim S, et al. Conformational changes in human prolyl-tRNA synthetase upon binding of the substrates proline and ATP and



- the inhibitor halofuginone. *Acta Crystallogr D Biol Crystallogr*. 2013;69(Pt 10):2136-45.
130. Nelson EF, Huang CW, Ewel JM, Chang AA, Yuan C. Halofuginone down-regulates Smad3 expression and inhibits the TGFbeta-induced expression of fibrotic markers in human corneal fibroblasts. *Molecular vision*. 2012;18:479-87.
131. Pines M, Domb A, Ohana M, Inbar J, Genina O, Alexiev R, et al. Reduction in dermal fibrosis in the tight-skin (Tsk) mouse after local application of halofuginone. *Biochemical pharmacology*. 2001;62(9):1221-7.
132. Zion O, Genin O, Kawada N, Yoshizato K, Roffe S, Nagler A, et al. Inhibition of transforming growth factor beta signaling by halofuginone as a modality for pancreas fibrosis prevention. *Pancreas*. 2009;38(4):427-35.
133. Gnainsky Y, Kushnirsky Z, Bilu G, Hagai Y, Genina O, Volpin H, et al. Gene expression during chemically induced liver fibrosis: effect of halofuginone on TGF-beta signaling. *Cell and tissue research*. 2007;328(1):153-66.
134. Roffe S, Hagai Y, Pines M, Halevy O. Halofuginone inhibits Smad3 phosphorylation via the PI3K/Akt and MAPK/ERK pathways in muscle cells: effect on myotube fusion. *Experimental cell research*. 2010;316(6):1061-9.
135. Spector I, Zilberstein Y, Lavy A, Nagler A, Genin O, Pines M. Involvement of host stroma cells and tissue fibrosis in pancreatic tumor development in transgenic mice. *PloS one*. 2012;7(7):e41833.
136. Halevy O, Nagler A, Levi-Schaffer F, Genina O, Pines M. Inhibition of collagen type I synthesis by skin fibroblasts of graft versus host disease and scleroderma patients: effect of halofuginone. *Biochemical pharmacology*. 1996;52(7):1057-63.
137. Levi-Schaffer F, Nagler A, Slavin S, Knopov V, Pines M. Inhibition of collagen synthesis and changes in skin morphology in murine graft-versus-host disease and tight skin mice: effect of halofuginone. *The Journal of investigative dermatology*. 1996;106(1):84-8.
138. Bruck R, Genina O, Aeed H, Alexiev R, Nagler A, Avni Y, et al. Halofuginone to prevent and treat thioacetamide-induced liver fibrosis in rats. *Hepatology*. 2001;33(2):379-86.
139. Huebner KD, Jassal DS, Halevy O, Pines M, Anderson JE. Functional resolution of fibrosis in mdx mouse dystrophic heart and skeletal muscle by halofuginone. *American journal of physiology Heart and circulatory physiology*. 2008;294(4):H1550-61.
140. Spira G, Mawasi N, Paizi M, Anbinder N, Genina O, Alexiev R, et al. Halofuginone, a collagen type I inhibitor improves liver regeneration in cirrhotic rats. *Journal of hepatology*. 2002;37(3):331-9.
141. Popov Y, Patsenker E, Bauer M, Niedobitek E, Schulze-Krebs A, Schuppan D. Halofuginone induces matrix metalloproteinases in rat hepatic stellate cells via activation of p38 and NFkappaB. *The Journal of biological chemistry*. 2006;281(22):15090-8.

142. Zhou H, Sun L, Yang XL, Schimmel P. ATP-directed capture of bioactive herbal-based medicine on human tRNA synthetase. *Nature*. 2013;494(7435):121-4.
143. Chu TL, Guan Q, Nguan CY, Du C. Halofuginone suppresses T cell proliferation by blocking proline uptake and inducing cell apoptosis. *International immunopharmacology*. 2013;16(4):414-23.
144. Singh RP, Hasan S, Sharma S, Nagra S, Yamaguchi DT, Wong DT, et al. Th17 cells in inflammation and autoimmunity. *Autoimmun Rev*. 2014;13(12):1174-81.
145. Kamberov YG, Kim J, Mazitschek R, Kuo WP, Whitman M. Microarray profiling reveals the integrated stress response is activated by halofuginone in mammary epithelial cells. *BMC Res Notes*. 2011;4:381.
146. Elkin M, Miao HQ, Nagler A, Aingorn E, Reich R, Hemo I, et al. Halofuginone: a potent inhibitor of critical steps in angiogenesis progression. *FASEB J*. 2000;14(15):2477-85.
147. Nagler A, Pines M. Topical treatment of cutaneous chronic graft versus host disease with halofuginone: a novel inhibitor of collagen type I synthesis. *Transplantation*. 1999;68(11):1806-9.
148. Koon HB, Fingleton B, Lee JY, Geyer JT, Cesarman E, Parise RA, et al. Phase II AIDS Malignancy Consortium trial of topical halofuginone in AIDS-related Kaposi sarcoma. *J Acquir Immune Defic Syndr*. 2011;56(1):64-8.
149. Pines M, Snyder D, Yarkoni S, Nagler A. Halofuginone to treat fibrosis in chronic graft-versus-host disease and scleroderma. *Biol Blood Marrow Transplant*. 2003;9(7):417-25.
150. de Jonge MJ, Dumez H, Verweij J, Yarkoni S, Snyder D, Lacombe D, et al. Phase I and pharmacokinetic study of halofuginone, an oral quinazolinone derivative in patients with advanced solid tumours. *European journal of cancer*. 2006;42(12):1768-74.
151. Neuhold LA, Killar L, Zhao W, Sung ML, Warner L, Kulik J, et al. Postnatal expression in hyaline cartilage of constitutively active human collagenase-3 (MMP-13) induces osteoarthritis in mice. *J Clin Invest*. 2001;107(1):35-44.
152. Roach HI, Yamada N, Cheung KS, Tilley S, Clarke NM, Oreffo RO, et al. Association between the abnormal expression of matrix-degrading enzymes by human osteoarthritic chondrocytes and demethylation of specific CpG sites in the promoter regions. *Arthritis and rheumatism*. 2005;52(10):3110-24.
153. Goldring MB, Birkhead JR, Suen LF, Yamin R, Mizuno S, Glowacki J, et al. Interleukin-1 beta-modulated gene expression in immortalized human chondrocytes. *The Journal of clinical investigation*. 1994;94(6):2307-16.
154. Lorenz J, Grassel S. Experimental osteoarthritis models in mice. *Methods in molecular biology*. 2014;1194:401-19.
155. Glasson SS, Chambers MG, Van Den Berg WB, Little CB. The OARSI histopathology initiative - recommendations for histological assessments of osteoarthritis in the mouse. *Osteoarthritis Cartilage*. 2010;18 Suppl 3:S17-23.

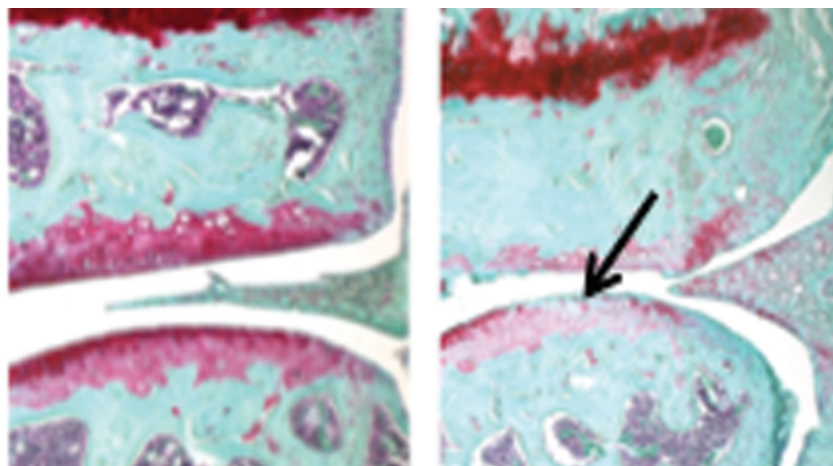
156. Rahman MM, Kopec JA, Sayre EC, Greidanus NV, Aghajanian J, Anis AH, et al. Effect of sociodemographic factors on surgical consultations and hip or knee replacements among patients with osteoarthritis in British Columbia, Canada. *J Rheumatol.* 2011;38(3):503-9.
157. Pfander D, Heinz N, Rothe P, Carl HD, Swoboda B. Tenascin and aggrecan expression by articular chondrocytes is influenced by interleukin 1beta: a possible explanation for the changes in matrix synthesis during osteoarthritis. *Ann Rheum Dis.* 2004;63(3):240-4.
158. Meulenbelt I, Seymour AB, Nieuwland M, Huizinga TW, van Duijn CM, Slagboom PE. Association of the interleukin-1 gene cluster with radiographic signs of osteoarthritis of the hip. *Arthritis Rheum.* 2004;50(4):1179-86.
159. Sakkas LI, Johanson NA, Scanzello CR, Platsoucas CD. Interleukin-12 is expressed by infiltrating macrophages and synovial lining cells in rheumatoid arthritis and osteoarthritis. *Cell Immunol.* 1998;188(2):105-10.
160. Campo GM, Avenoso A, D'Ascola A, Scuruchi M, Prestipino V, Calatroni A, et al. Hyaluronan in part mediates IL-1beta-induced inflammation in mouse chondrocytes by up-regulating CD44 receptors. *Gene.* 2012;494(1):24-35.
161. Liacini A, Sylvester J, Li WQ, Huang W, Dehnade F, Ahmad M, et al. Induction of matrix metalloproteinase-13 gene expression by TNF-alpha is mediated by MAP kinases, AP-1, and NF-kappaB transcription factors in articular chondrocytes. *Exp Cell Res.* 2003;288(1):208-17.
162. Troeberg L, Nagase H. Proteases involved in cartilage matrix degradation in osteoarthritis. *Biochim Biophys Acta.* 2012;1824(1):133-45.
163. Song RH, Tortorella MD, Malfait AM, Alston JT, Yang Z, Arner EC, et al. Aggrecan degradation in human articular cartilage explants is mediated by both ADAMTS-4 and ADAMTS-5. *Arthritis Rheum.* 2007;56(2):575-85.
164. Imai K, Ohta S, Matsumoto T, Fujimoto N, Sato H, Seiki M, et al. Expression of membrane-type 1 matrix metalloproteinase and activation of progelatinase A in human osteoarthritic cartilage. *Am J Pathol.* 1997;151(1):245-56.
165. Billingham RC, Dahlberg L, Ionescu M, Reiner A, Bourne R, Rorabeck C, et al. Enhanced cleavage of type II collagen by collagenases in osteoarthritic articular cartilage. *J Clin Invest.* 1997;99(7):1534-45.
166. Freemont AJ, Hampson V, Tilman R, Goupille P, Taiwo Y, Hoyland JA. Gene expression of matrix metalloproteinases 1, 3, and 9 by chondrocytes in osteoarthritic human knee articular cartilage is zone and grade specific. *Ann Rheum Dis.* 1997;56(9):542-9.
167. Kaspiris A, Khaldi L, Grivas TB, Vasiliadis E, Kouvaras I, Dagkas S, et al. Subchondral cyst development and MMP-1 expression during progression of osteoarthritis: an immunohistochemical study. *Orthop Traumatol Surg Res.* 2013;99(5):523-9.
168. Nam J, Perera P, Liu J, Rath B, Deschner J, Gassner R, et al. Sequential alterations in catabolic and anabolic gene expression parallel pathological changes

- during progression of monoiodoacetate-induced arthritis. *PLoS One*. 2011;6(9):e24320.
169. Little CB, Barai A, Burkhardt D, Smith SM, Fosang AJ, Werb Z, et al. Matrix metalloproteinase 13-deficient mice are resistant to osteoarthritic cartilage erosion but not chondrocyte hypertrophy or osteophyte development. *Arthritis Rheum*. 2009;60(12):3723-33.
170. Takaishi H, Kimura T, Dalal S, Okada Y, D'Armiento J. Joint diseases and matrix metalloproteinases: a role for MMP-13. *Curr Pharm Biotechnol*. 2008;9(1):47-54.
171. Zhao W, Zhang C, Shi M, Zhang J, Li M, Xue X, et al. The discoidin domain receptor 2/annexin A2/matrix metalloproteinase 13 loop promotes joint destruction in arthritis through promoting migration and invasion of fibroblast-like synoviocytes. *Arthritis Rheumatol*. 2014;66(9):2355-67.
172. Pines M, Spector I. Halofuginone - the multifaceted molecule. *Molecules*. 2015;20(1):573-94.
173. Liang J, Zhang B, Shen RW, Liu JB, Gao MH, Li Y, et al. Preventive effect of halofuginone on concanavalin A-induced liver fibrosis. *PLoS One*. 2013;8(12):e82232.
174. Morales TI, Joyce ME, Sobel ME, Danielpour D, Roberts AB. Transforming growth factor-beta in calf articular cartilage organ cultures: synthesis and distribution. *Arch Biochem Biophys*. 1991;288(2):397-405.
175. Homandberg GA, Hui F, Wen C, Purple C, Bewsey K, Koepf H, et al. Fibronectin-fragment-induced cartilage chondrolysis is associated with release of catabolic cytokines. *Biochem J*. 1997;321 ( Pt 3):751-7.
176. Pombo-Suarez M, Castano-Oreja MT, Calaza M, Gomez-Reino J, Gonzalez A. Differential upregulation of the three transforming growth factor beta isoforms in human osteoarthritic cartilage. *Ann Rheum Dis*. 2009;68(4):568-71.
177. Kapetanakis S, Drygiannakis I, Kazakos K, Papanas N, Kolios G, Kouroumalis E, et al. Serum TGF-beta2 and TGF-beta3 are increased and positively correlated to pain, functionality, and radiographic staging in osteoarthritis. *Orthopedics*. 2010;33(8).
178. Xavier S, Piek E, Fujii M, Javelaud D, Mauviel A, Flanders KC, et al. Amelioration of radiation-induced fibrosis: inhibition of transforming growth factor-beta signaling by halofuginone. *J Biol Chem*. 2004;279(15):15167-76.
179. Elkin M, Ariel I, Miao HQ, Nagler A, Pines M, de-Groot N, et al. Inhibition of bladder carcinoma angiogenesis, stromal support, and tumor growth by halofuginone. *Cancer Res*. 1999;59(16):4111-8.
180. Pinthus JH, Sheffer Y, Nagler A, Fridman E, Mor Y, Genina O, et al. Inhibition of Wilms tumor xenograft progression by halofuginone is accompanied by activation of WT-1 gene expression. *J Urol*. 2005;174(4 Pt 2):1527-31.
181. van Kempen LC, Rijntjes J, Mamor-Cornelissen I, Vincent-Naulleau S, Gerritsen MJ, Ruiters DJ, et al. Type I collagen expression contributes to angiogenesis

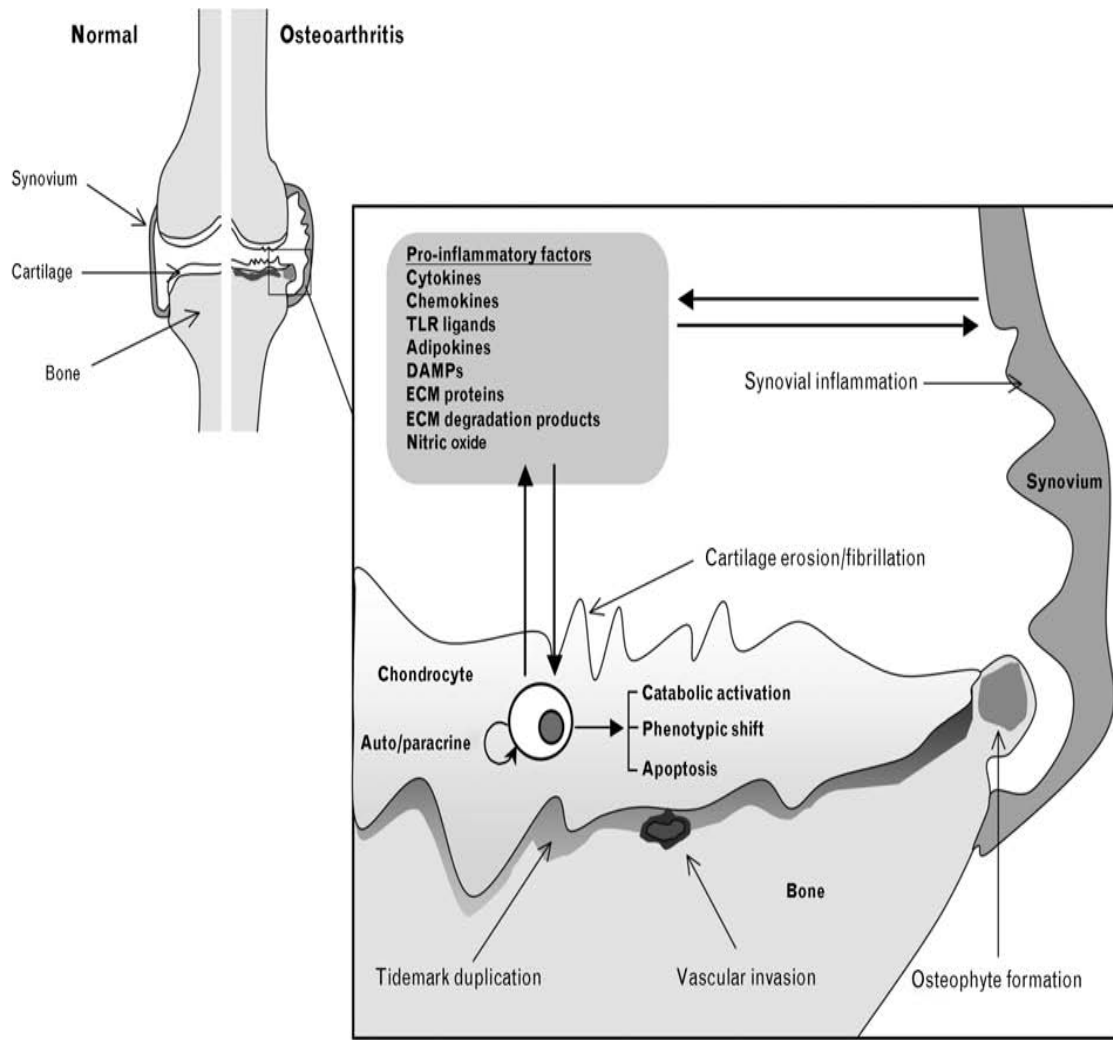
- and the development of deeply invasive cutaneous melanoma. *Int J Cancer*. 2008;122(5):1019-29.
182. Spector I, Honig H, Kawada N, Nagler A, Genin O, Pines M. Inhibition of pancreatic stellate cell activation by halofuginone prevents pancreatic xenograft tumor development. *Pancreas*. 2010;39(7):1008-15.
183. Gavish Z, Pinthus JH, Barak V, Ramon J, Nagler A, Eshhar Z, et al. Growth inhibition of prostate cancer xenografts by halofuginone. *Prostate*. 2002;51(2):73-83.
184. Jiang S, Zeng Q, Gettayacamin M, Tungtaeng A, Wannaying S, Lim A, et al. Antimalarial activities and therapeutic properties of febrifugine analogs. *Antimicrob Agents Chemother*. 2005;49(3):1169-76.
185. Shabgah AG, Fattahi E, Shahneh FZ. Interleukin-17 in human inflammatory diseases. *Postepy Dermatol Alergol*. 2014;31(4):256-61.

## FIGURES AND TABLES

---

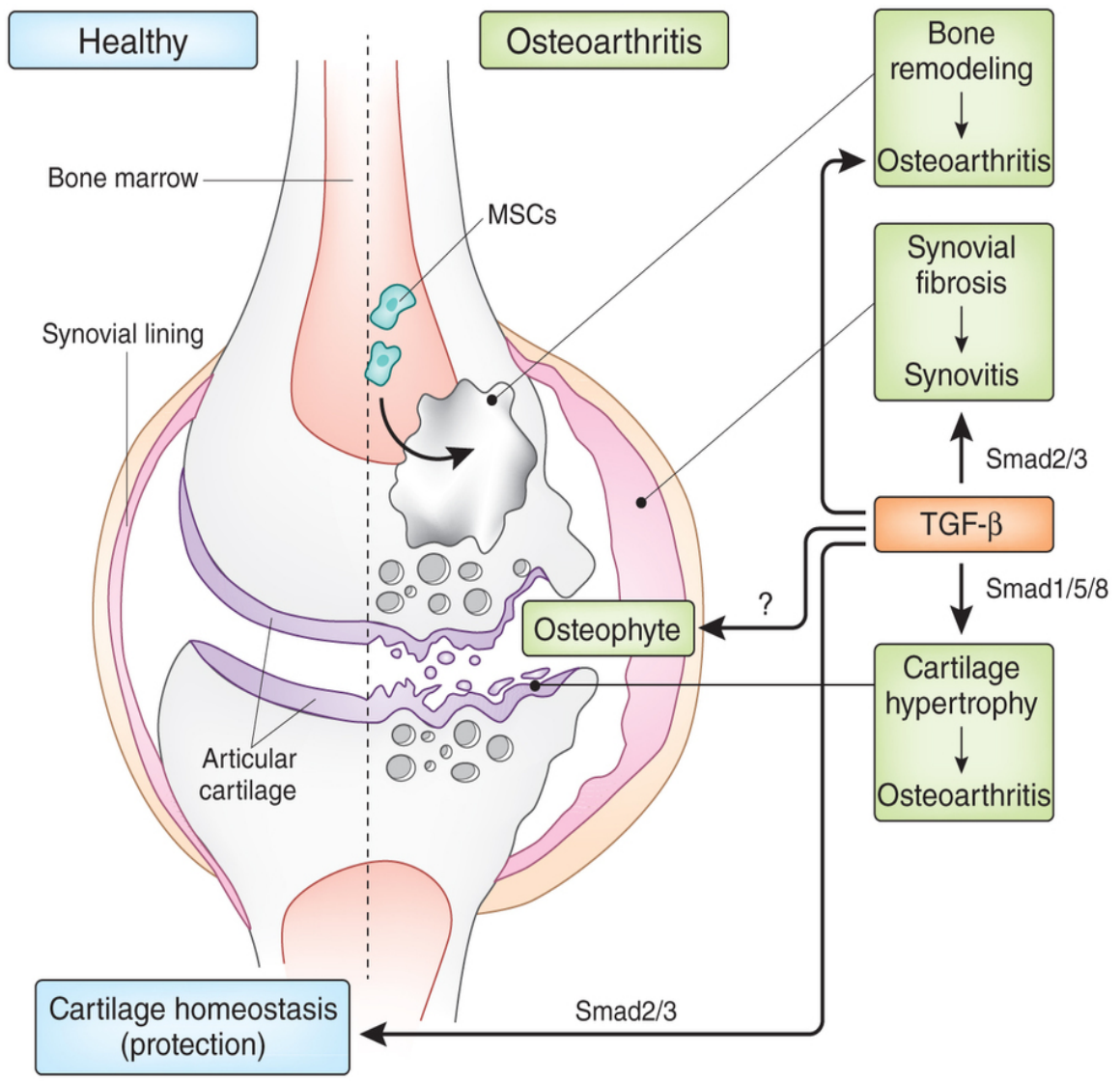


**Figure 1:** Destruction of cartilage in an Osteoarthritic joint (Right image, pointed by Black arrow) compared to an intact cartilage in a healthy joint (Left image)



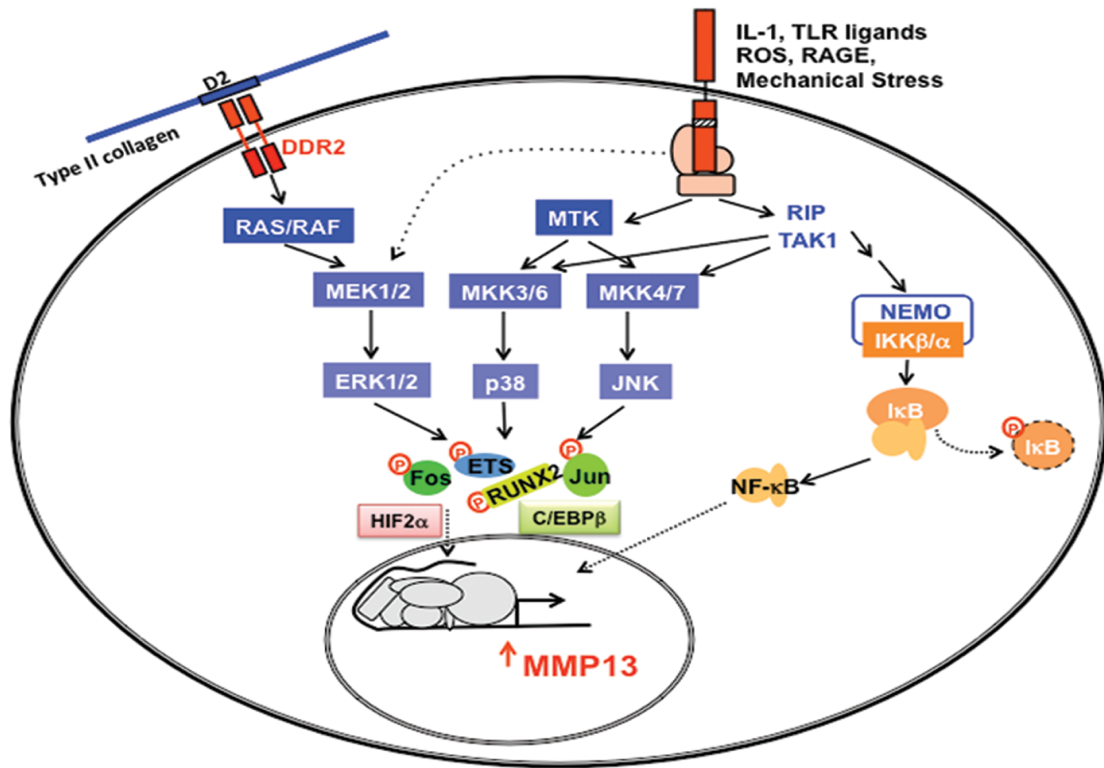
**Figure-2:** Biomechanical stress, leads to up-regulation of the synthetic activity and the inflammatory cytokines, chemokines, adipokines, Toll-like receptor (TLR) ligands, and other inflammatory mediators such as nitric oxide. The upregulation of cartilage-degrading proteinases by extracellular matrix (ECM) proteins and products can promote catabolic activation, phenotypic shift, and apoptosis.

Osteoarthritis. *Current opinion in rheumatology*. 2011;23(5):471-8. Figure used with permission.



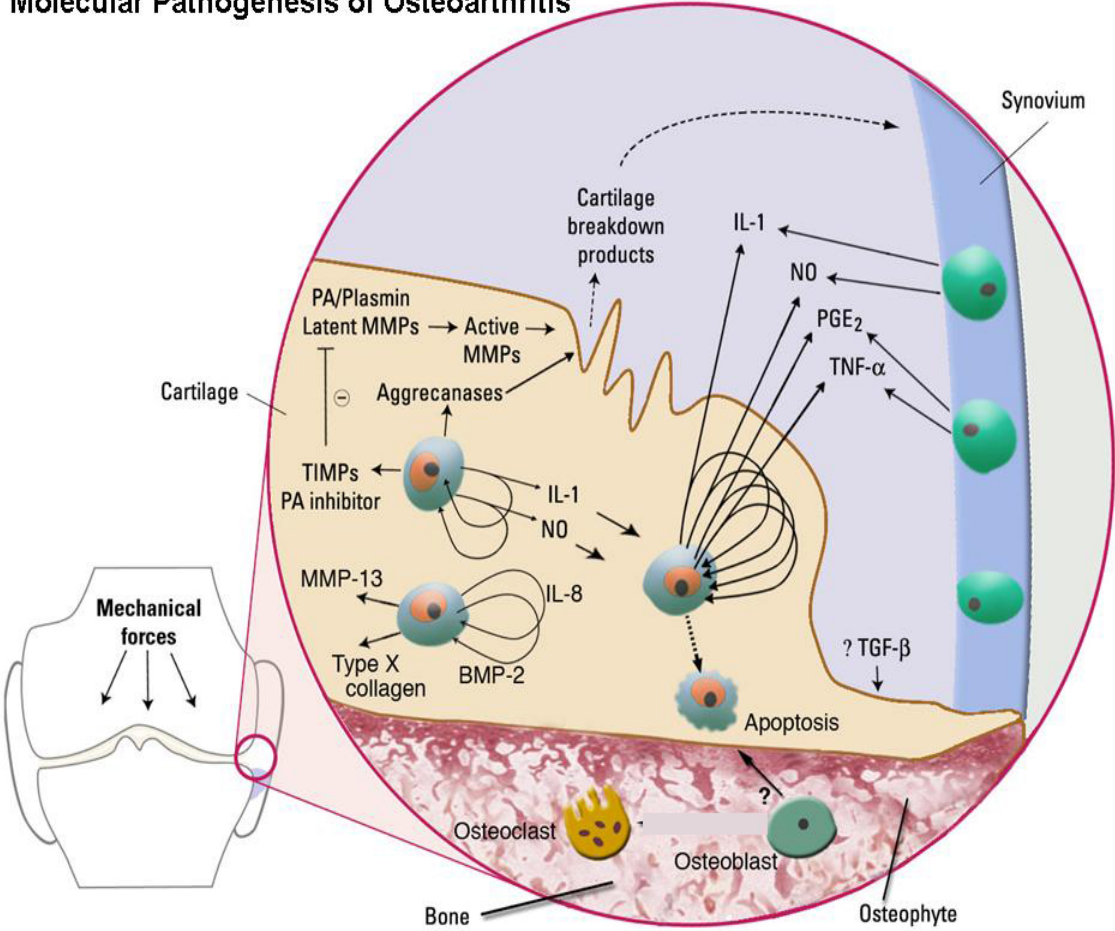
**Figure-3:** Effects of TGF-β signaling on healthy and osteoarthritic cartilage  
 TGF-β and osteoarthritis--the good and the bad. Nat Med. 2013 Jun;19(6):667-9. doi: 10.1038/nm.3228. Figure used with permission.



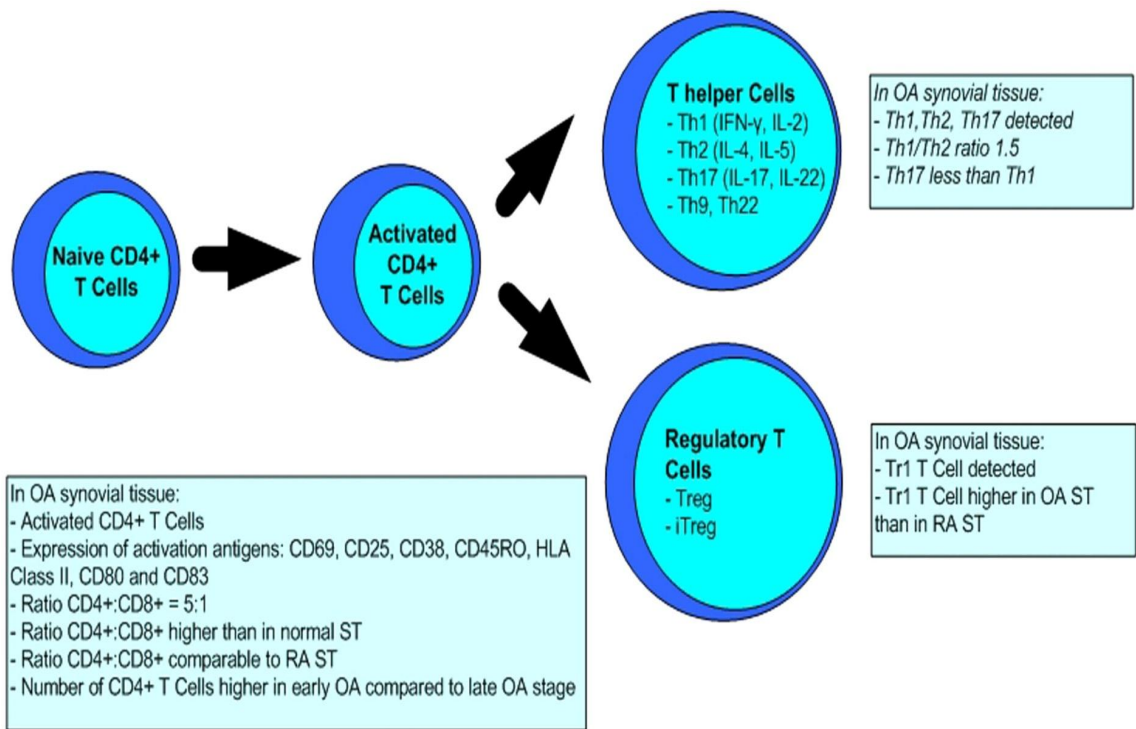


**Figure-4:** Stimulation of receptors for type II collagen fragments, activates the production of matrix degrading proteinases and inflammatory cytokines which leads to release of ROS and production of MMP-13.

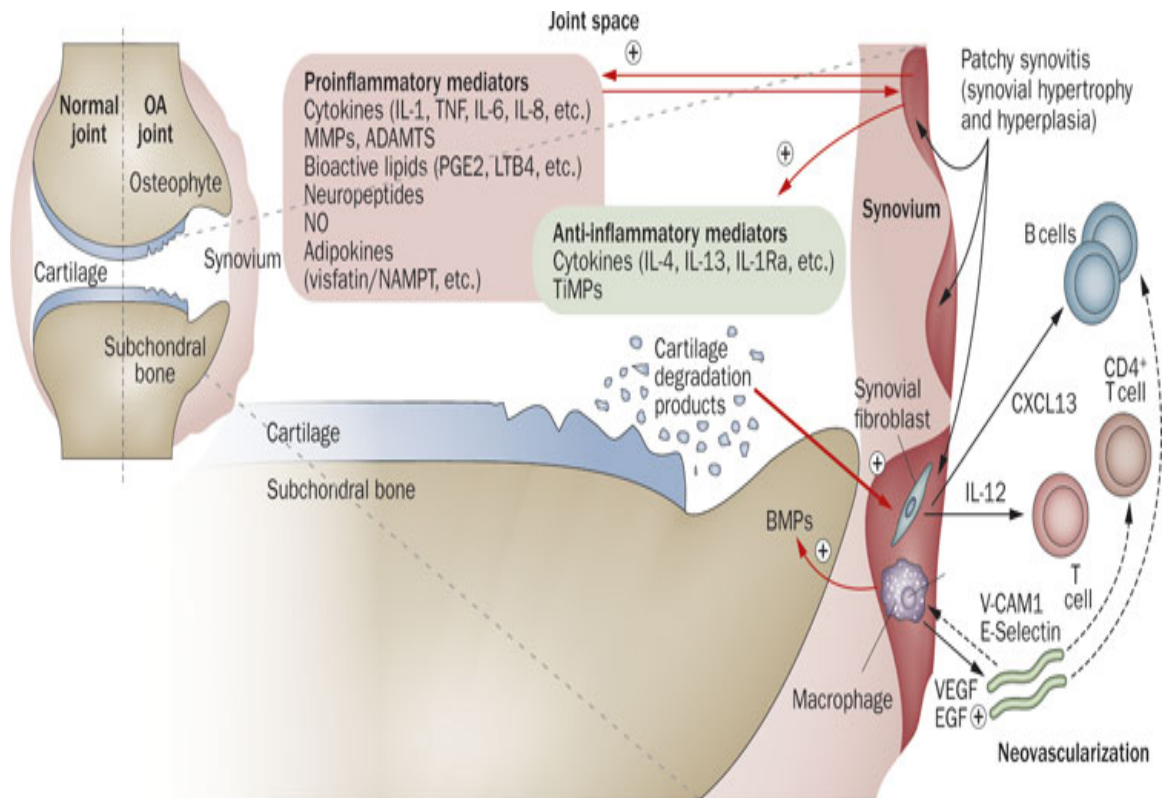
**Molecular Pathogenesis of Osteoarthritis**



**Figure-5:** Molecular pathogenesis of osteoarthritis under mechanical stress. Nat Clin Pract Rheumatol. 2006 Jun;2(6):304-12. Figure used with permission.

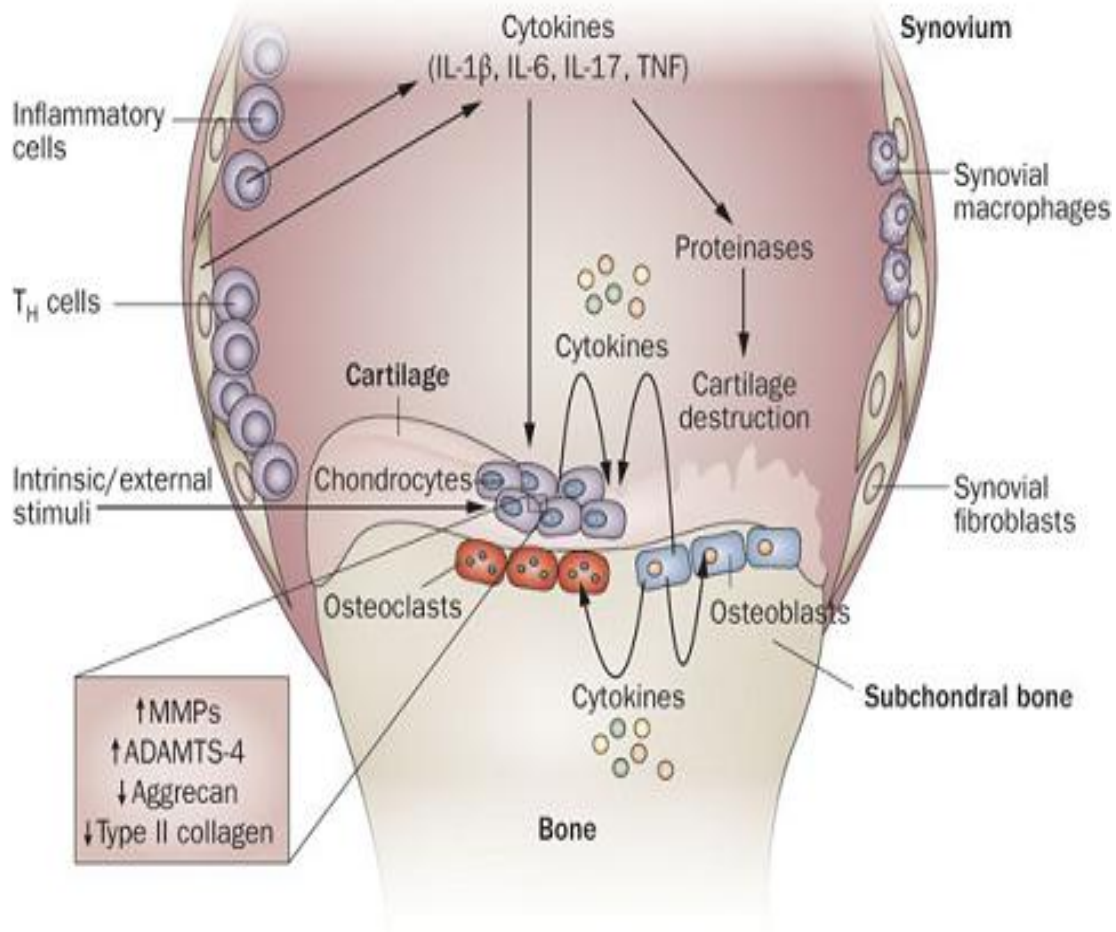


**Figure-6:** Th cells lineage (Th1, Th2 and Th17) , T regulatory (Treg) cells and induced T regulatory (iTreg) cells (Th3 and Tr1) in Osteoarthritis



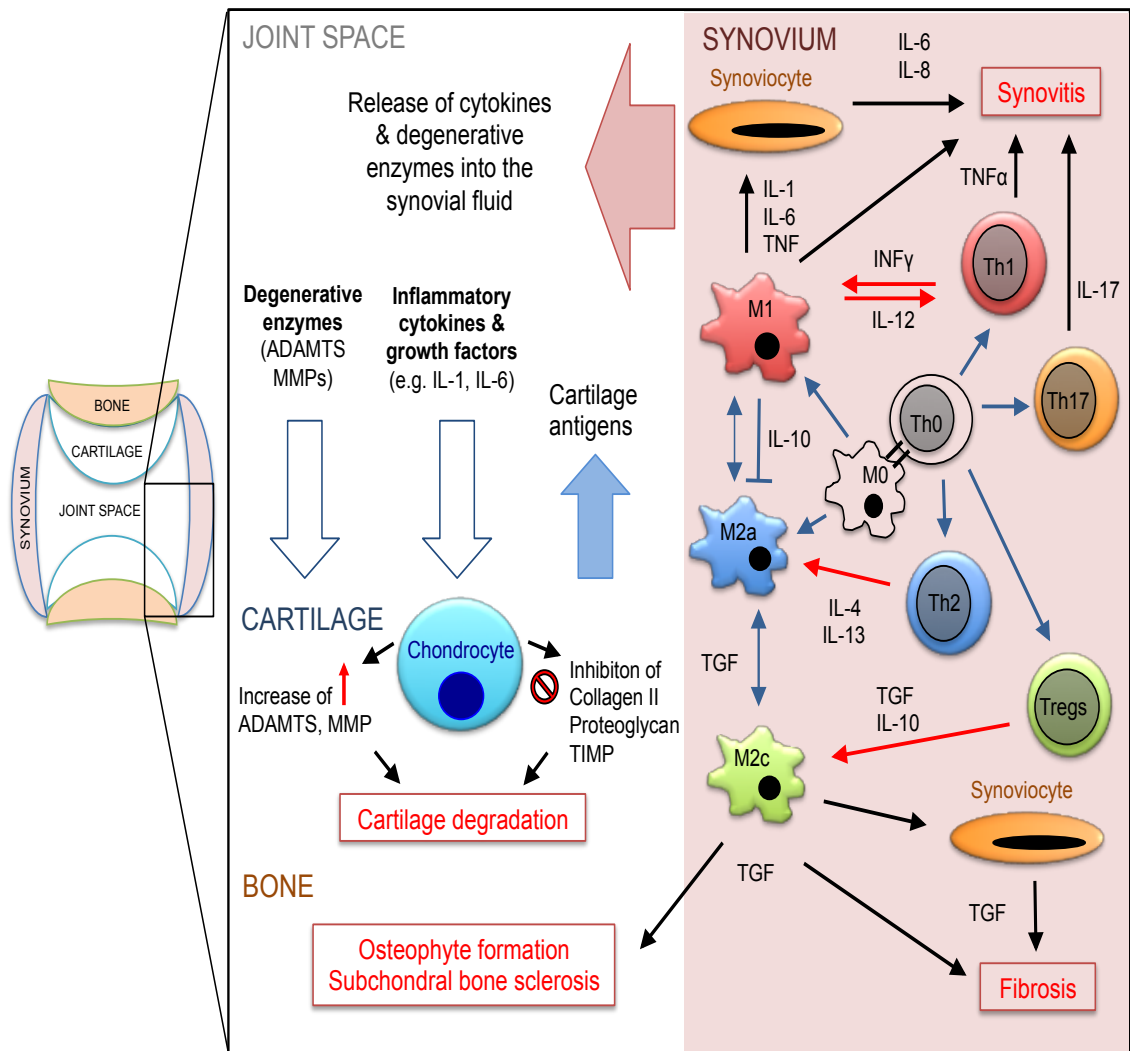
**Figure-7:** Involvement of the synovium in OA pathophysiology

Sellam, J. & Berenbaum, F. (2010) The role of synovitis in pathophysiology and clinical symptoms of osteoarthritis *Nat. Rev. Rheumatol.* doi:10.1038/nrrheum.2010.159. Figure used with permission.



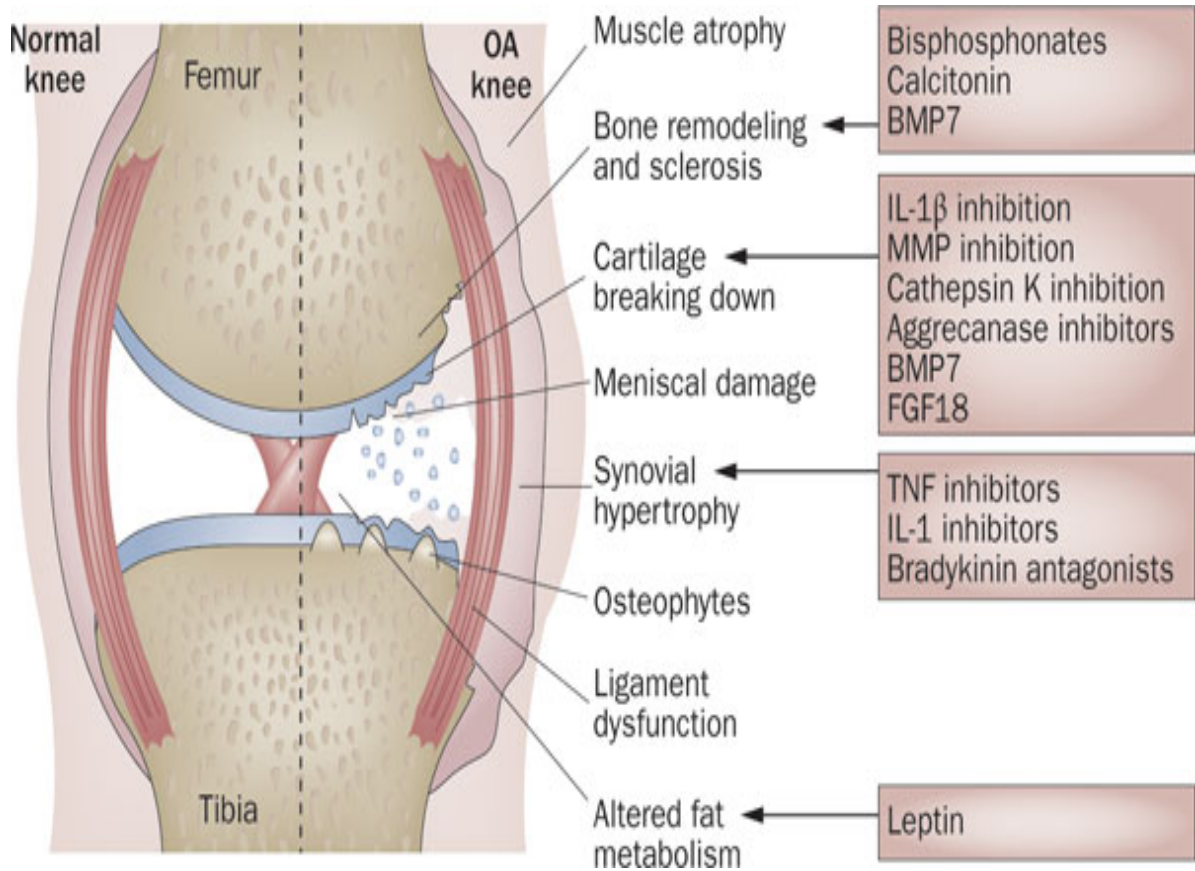
**Figure-8:** The role of proinflammatory cytokines in the pathophysiology of OA.

Role of proinflammatory cytokines in the pathophysiology of osteoarthritis. *Nat Rev Rheumatol.* 2011 Jan;7(1):33-42. doi: 10.1038/nrrheum.2010.196. Epub 2010 Nov 30. Figure used with permission.

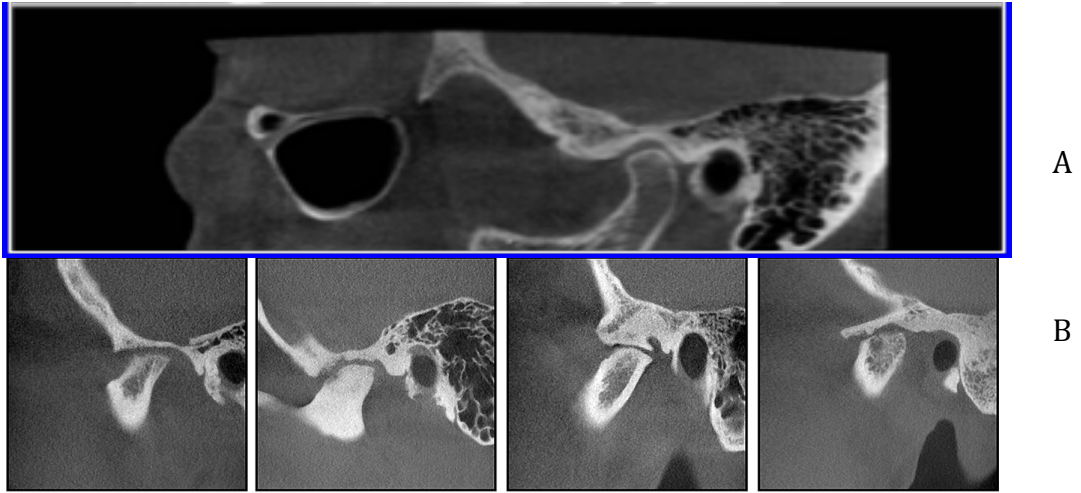


**Figure-9:** The role of Th17 in the Osteoarthritis



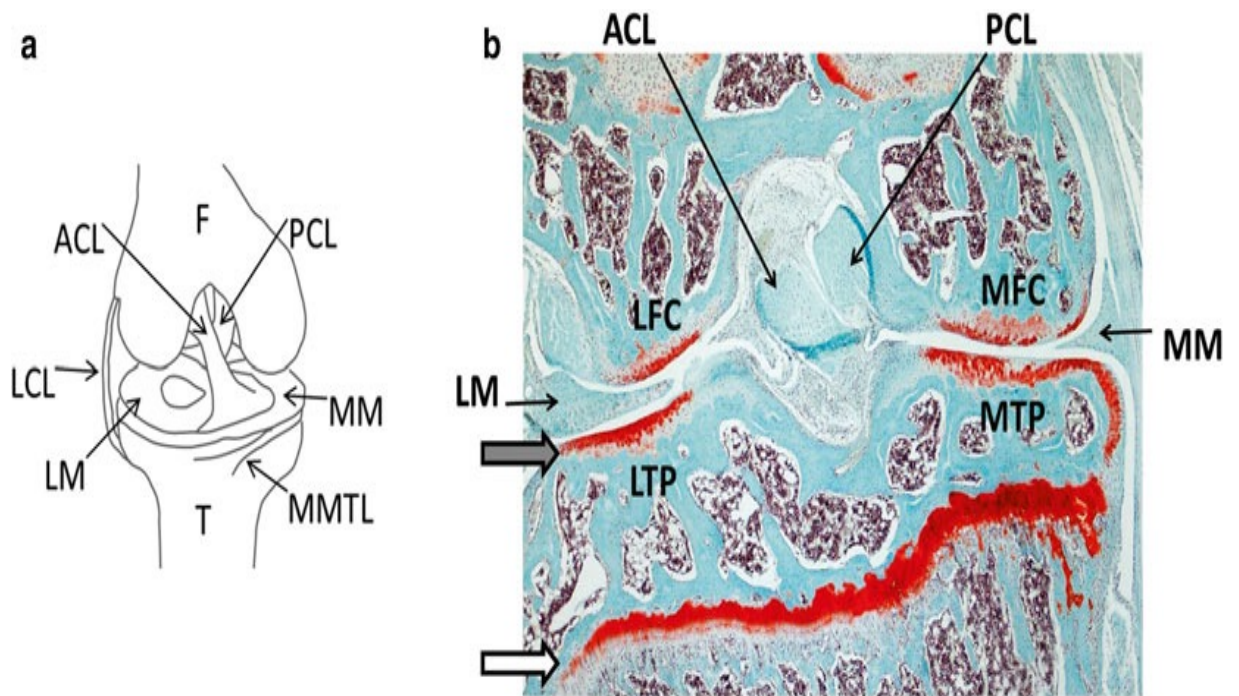


**Figure-10:** Pharmacologic therapies and the site of their impact.  
 Nat. Rev. Rheumatol. doi:10.1038/nrrheum.2010.178. Figure used with permission.



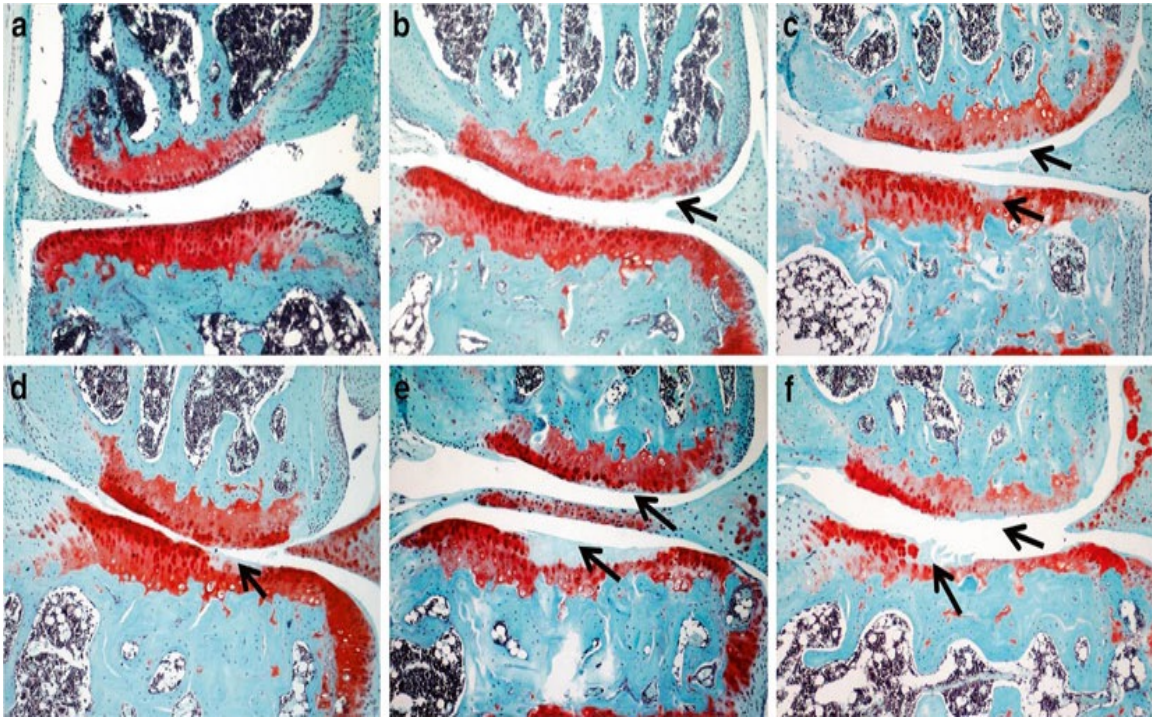
**Figure-11:** Osteoarthritic TMJs (B), CT scan view, compared to the normal Joint (A).  
Dentomaxillofacial Radiology (2015) 44, 20140235 . Pictures used with permission.





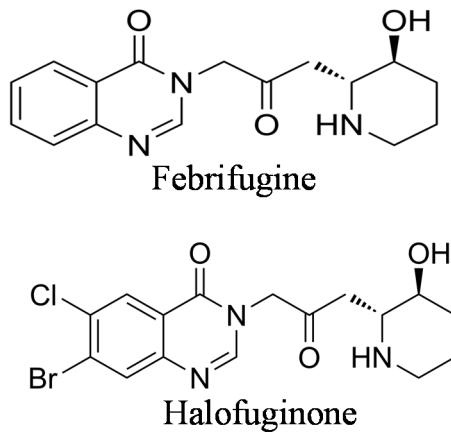
**Figure-12:** (a) Outline of a right knee joint. The MMTL is transected to generate destabilization of the medial meniscus (DMM) and the ACL is transected in the ACLT model. (b) Overview of Safranin-O stained of a mouse knee joint 4 weeks after DMM induction. *Grey arrow* indicates articular cartilage, *white arrow* indicates growth plate.  $\times 40$  magnification. ACL: anterior cruciate ligament; F = femur; LCL = lateral collateral ligament; LFC: lateral femoral condyle; LM = lateral meniscus; LTP: lateral tibial plateau; MFC: medial femoral condyle; MM: medial meniscus; MMTL = medial meniscotibial ligament; MTP: medial tibial plateau; PCL: posterior cruciate ligament; T = tibia .

Taken from Mouse genetics Methods and Protocols ISSN 1064-3745 , with permission.

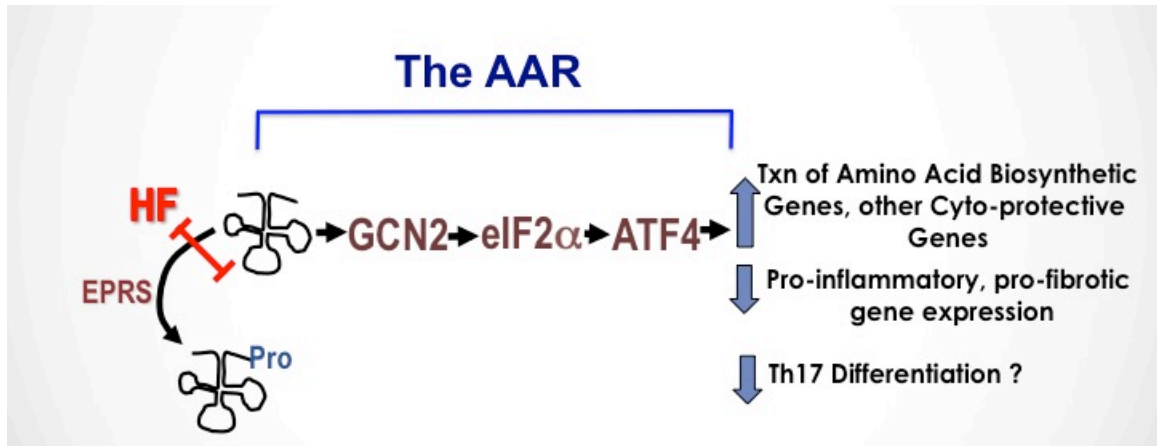


**Figure-13:** Osteoarthritis progression after DMM in wild-type mice. Osteoarthritis progression is demonstrated on medial areas of Safranin-O stained sections of right hind knee joints at 2 (**b**), 4 (**c**), 6 (**d**), 8 (**e**), and 12 (**f**) weeks after DMM surgery. (**a**) is the contra lateral joint. *Arrows* indicate articular cartilage damage of femoral condyle and tibial plateau. (**a–f**)  $\times 100$  magnification

Taken from Mouse genetics Methods and Protocols ISSN 1064-3745 , with permission.

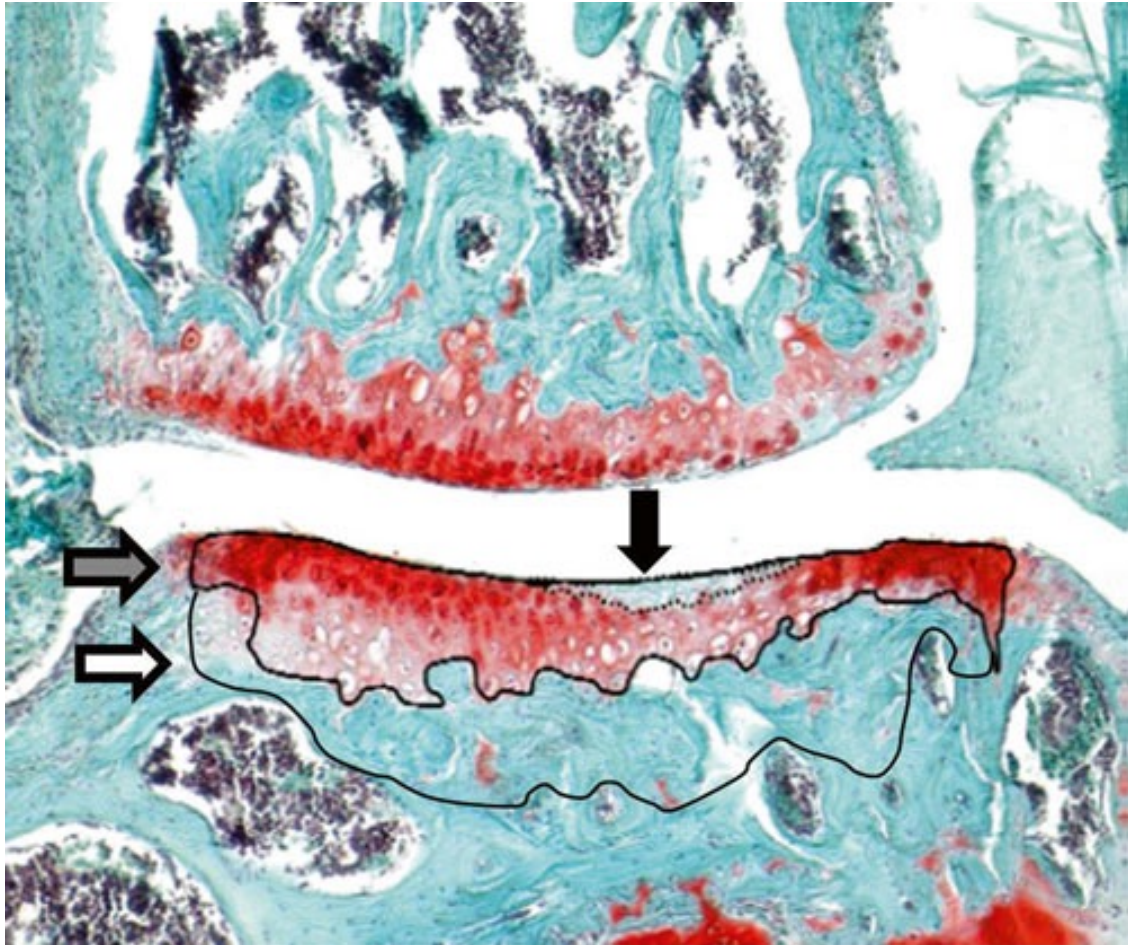


**Figure-14:** Chemical structures of Febrifugine and Halofuginone



**Figure-15:** AAR activation by HF inhibits prolyl tRNA charging enzyme EPRS by HF results in uncharged tRNA accumulation. Uncharged tRNA activates the sensor kinase GCN2, leading to phosphorylation of eif2a and changes in translation and transcription of pro-inflammatory genes





**Figure-16:** Here is a representative image for morphometrical evaluation of osteoarthritis using a Safranin-O stained section. The histology image has taken from a right knee joint 4 weeks after DMM surgery. Black arrow shows area of acellular/unstained cartilage, grey arrow is the whole cartilage area and white arrow refers to subchondral bone plate (SBP). At  $\times 100$  magnification.

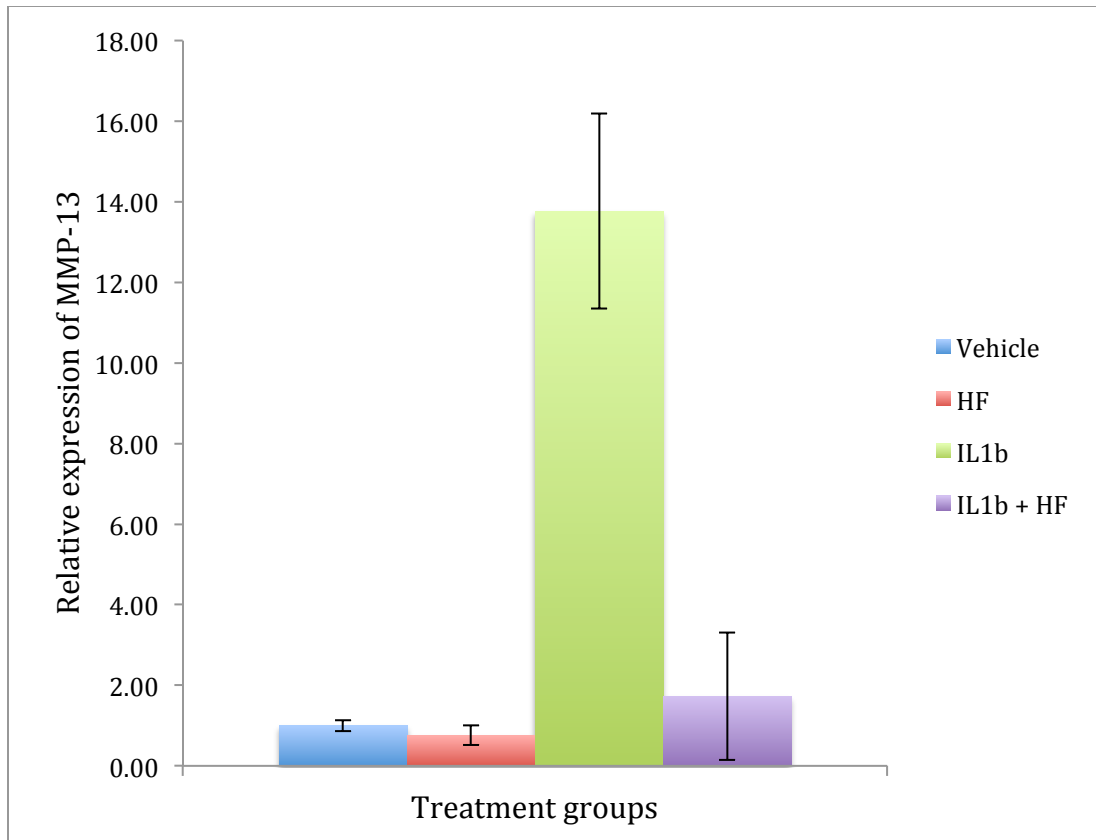


Figure 17: HF inhibits the expression of MMP-13 when it is co-incubated with the IL-1 $\beta$  in the CT28/I2 cells

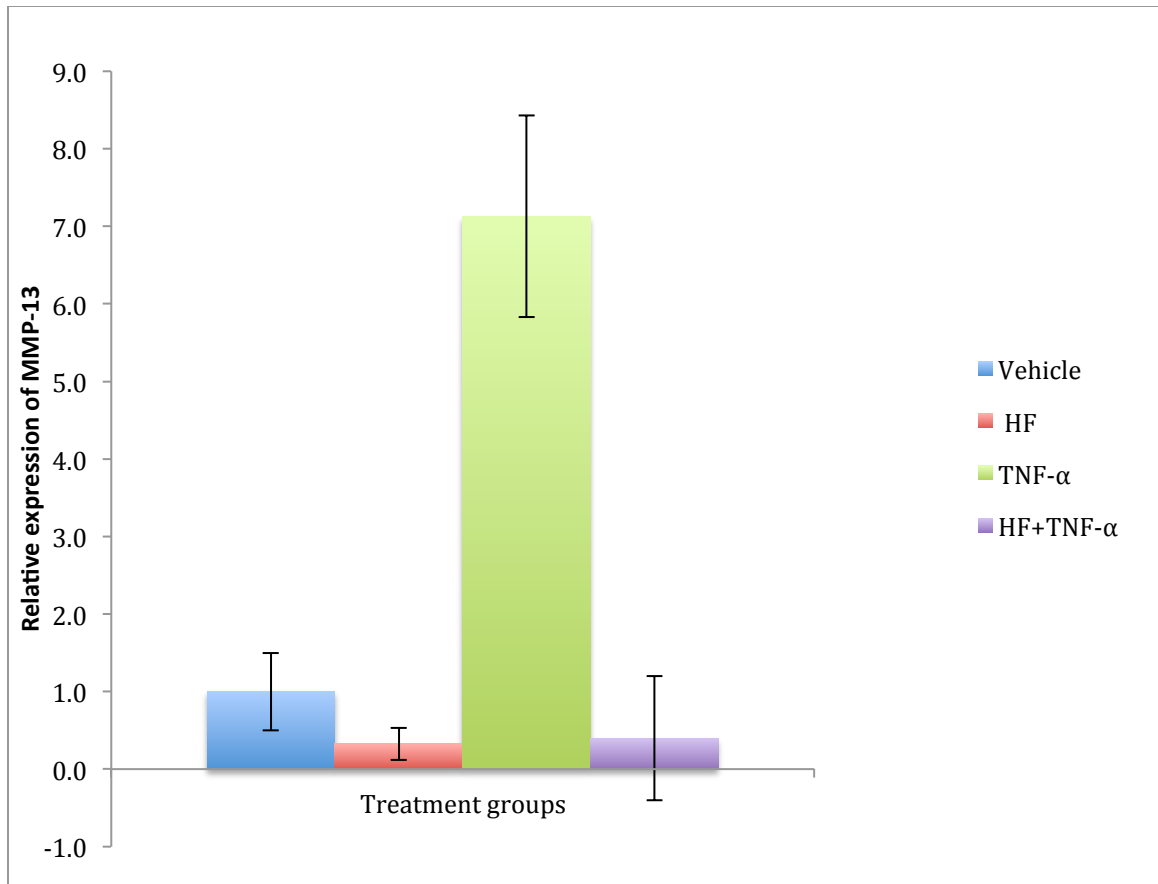


Figure 18: HF inhibits the expression of MMP-13 when it is co-incubated with the TNF- $\alpha$  in the CT28/I2 cells

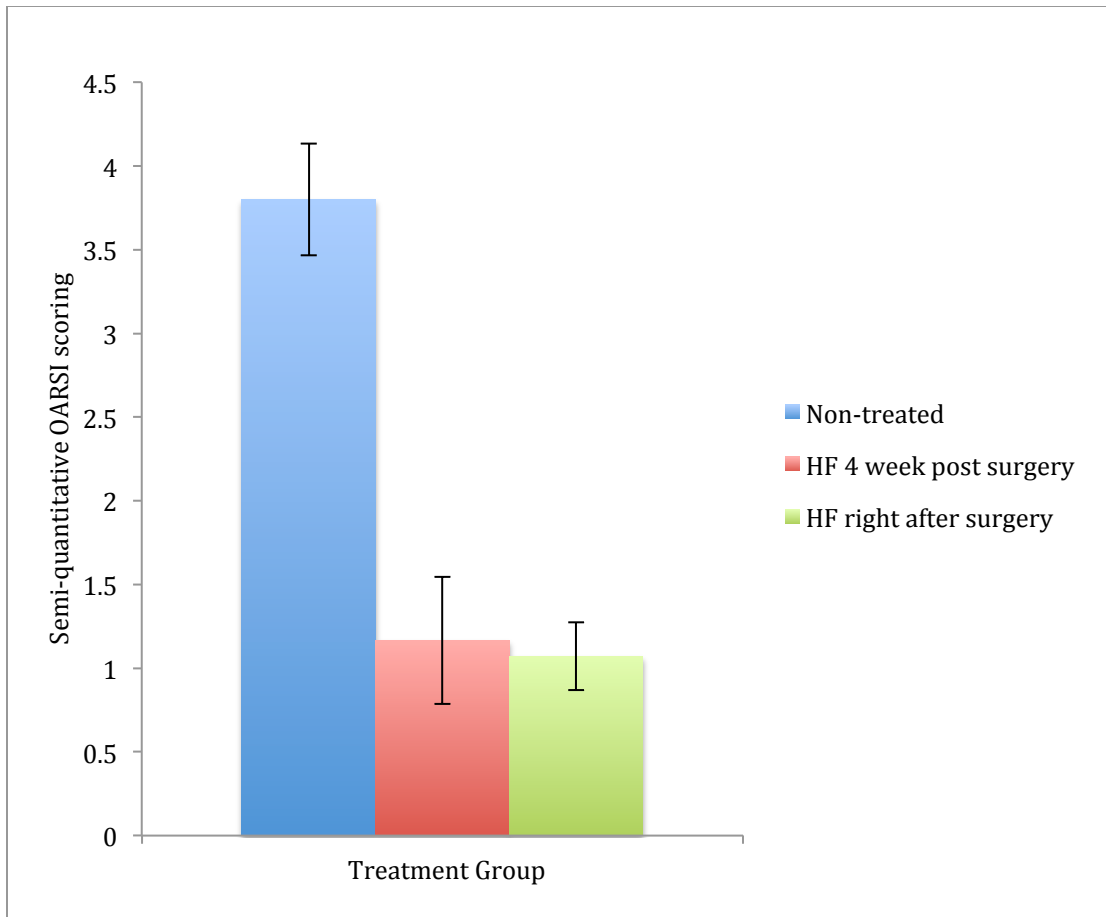


Figure 19: HF treatment reduced the progression of OA in DMM surgery osteoarthritis model

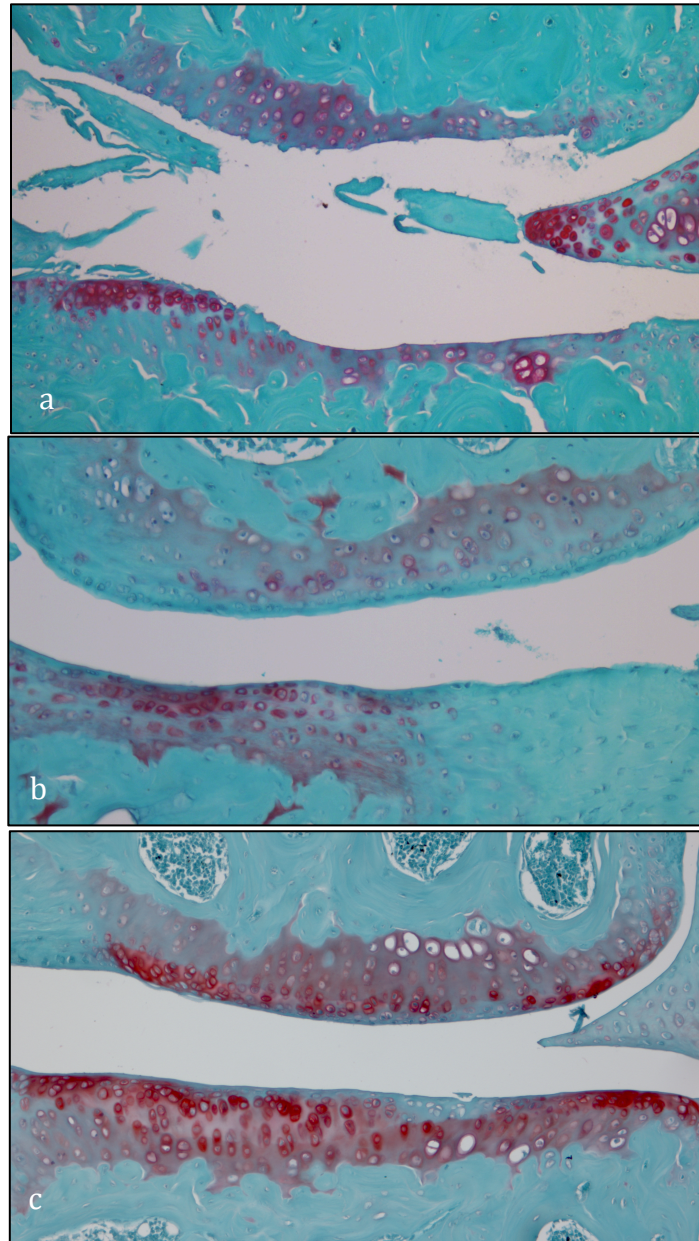
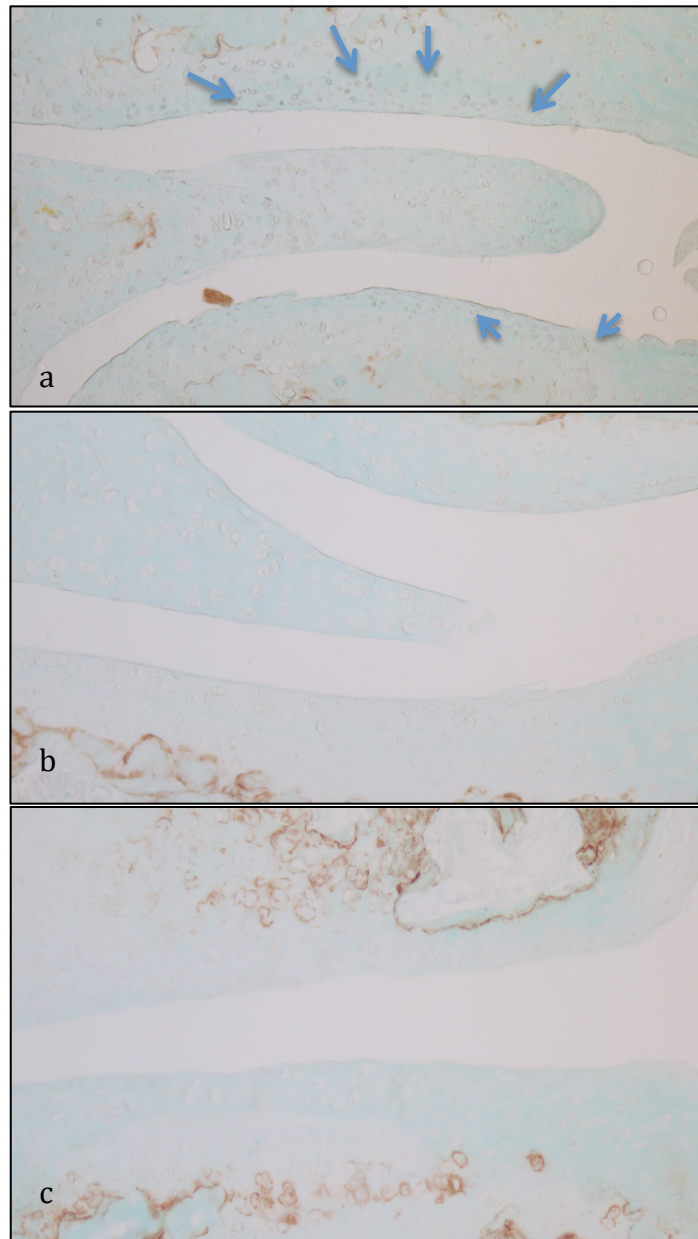


Figure 20: Safranin O/Fast green staining at 12 weeks after DMM surgery (10x magnification) (a) Control group (PBS injected, untreated animals) shows destruction of cartilage, wider erosion, irregular surface and demonstrates grade 5 OARSI semi-quantitative scoring. (b) Early treatment (HF injections 2 days post DMM surgery every other day for 12 weeks) demonstrates grade 0.5 OARSI semi-quantitative scoring (c) Late treatment (received Halofuginone injections 4 weeks post DMM surgery every other day for 8 weeks, and demonstrates grade 1 OARSI semi-quantitative scoring. In the treated animals (b and c) less cartilage destruction is observed compared to untreated animals (a).





**Figure 21:** Immunohistochemistry staining for MMP-13, in histological sections of osteoarthritic knee induced by DMM surgery in mice model (a) Control group (PBS injected, untreated animals) prominent expression of MMP-13 (*Brown spots pointed by blue arrows*) (b) Early treatment (received HF injections 2 days post DMM surgery every other day for 12 weeks) and MMP-13 is hardly detected (c) Late Treatment (received Halofuginone injections 4 weeks post DMM surgery every other day for 8 weeks, and MMP-13 expression is rare. In (b) and (c) there is significantly less MMP-13 signal observed compared to (a) 10x magnification

Level of evidence	Observation	References
<b>Clinical</b>	Effusion, Joint swelling or palpable synovitis Local signs of inflammation Sudden increase in pain Night pain and morning stiffness	Krasnokutsky et al (2008), Ayrál(1999)
<b>Imaging</b>	Gadolinium-enhanced synovium and increased synovial volume detected by MRI Correlation between MRI and histological observations Synovitis seen using ultrasonography of symptomatic joints Association between ultrasound-detected synovitis and clinical symptoms of synovitis Macroscopic synovial changes detected by arthroscopy in about half of patients with knee OA Arthroscopic synovitis associated with progression of knee OA	Loeuille et al (2005), Fernandez-Madrid et al (1995), Ostergaard et al (1997), D'Agostino et al (2005), Keen et al (2008), Ayrál et al (1999), Ayrál et al (2005)
<b>Histological</b>	Synovial hypertrophy and hyperplasia Infiltration of mononuclear cells (monocytes/macrophages, activated B cells and T cells) Adaptive immune T-cell and B-cell responses to fragments of extracellular matrix Increased angiogenesis Synovitis in the velocity of degenerative cartilage	Ayrál et al (2005), Myers et al (1990), Walsh et al (2007), Shibakawa et al (2003), Nakamura et al (1999), Alsamed et al (1990), Sellam J et al (2010), Gobezie R et al (2007), Gierman LM (2012), Maldonado M (2013)
<b>Molecular</b>	Production and/or release of proinflammatory cytokines (TNF, IL-1 $\beta$ , IL-6, IL-8, IL-15, IL-17, IL-21) Increased production of PGE2 and nitric oxide Increased activity of MMPs Production of adipokines Release of EGF and VEGF Involvement of macrophages in osteophyte formation via BMPs Release of proinflammatory and pain neurotransmitters (substance P, NGF)	Benito et al (2005), Smith et al (1997), Shibakawa et al (2003), Yuan et al (2004), Farahat et al (2003), Furuzawa-Carballeda & Alcocer-Varela (1999), Scanzello et al (2009), Brentano et al (2007), Presle et al (2006), Nissalo et al (2002), Raychaudhuri & Raychaudhuri (2009)
<b>Biological Markers</b>	Increased levels of CRP (detected by ultrasensitive assay) Increased levels of MMP-13, MMP-3 and MMP-9	Pearle et al (2007), Conrozier et al (2000), Masuhara et al (2002)

Table-1: Evidence of inflammation in OA

<b>Groups</b>	<b>Day1</b>	<b>Day2</b>	<b>Day3</b>	<b>Day4</b>
<b>- HF - IL-1<math>\beta</math>/TNF-<math>\alpha</math></b>	10% FBS	1% FBS		
<b>+ HF - IL-1<math>\beta</math>/TNF-<math>\alpha</math></b>	10% FBS	1% FBS	+ 200 nM HF	
<b>- HF +IL-1<math>\beta</math>/TNF-<math>\alpha</math></b>	10% FBS	1% FBS		+10ng/ml IL-1 $\beta$ /TNF- $\alpha$
<b>+HF +IL-1<math>\beta</math>/TNF-<math>\alpha</math></b>	10% FBS	1% FBS	+ 200 nM HF	+10ng/ml IL-1 $\beta$ /TNF- $\alpha$

**Table-2:** Experimental conditions for qPCR experiments. Medium and supplements were added to the chondrocytes culture medium at the following concentrations: Halofuginone (200nM per well), IL-1 $\beta$  (10ng/ml)/ TNF- $\alpha$  (10ng/ml)

Grade	Osteoarthritic damage
0	Normal
0.5	Loss of Safranin-O without structural changes
1	Small fibrillation without loss of Cartilage
2	Vertical clefts down to the layer immediately below the superficial layer and some loss of surface lamina
3	Vertical clefts/erosion to the calcified cartilage extending to <25% of the articular surface
4	Vertical clefts/erosion to the calcified cartilage extending to <25-50% of the articular surface
5	Vertical clefts/erosion to the calcified cartilage extending to <50-75% of the articular surface
6	Vertical clefts/erosion to the calcified cartilage extending to >75% of the articular surface

**Table-3:** Semi-quantitative Modified Mankin scoring system recommended from OARSI.